

RESECTION OF CANCERS OF THE BASE OF TONGUE

Johan Fagan

Cancers of the base of tongue (BOT) may be treated with primary surgery, and/or irradiation, and/or chemoradiation therapy. Both the oncology team and patient need to carefully weigh up morbidity vs. cure of surgical and nonsurgical options, both of which may cause significant morbidity. Patients need to be carefully assessed relating to their ability to deal with a measure of aspiration, access to speech and swallowing services and to PEG feeding should they not resume oral feeding.

Surgical approaches

Surgeons have to be *au fait* with the full range of surgical approaches and reconstructive options so as to ensure complete resection, minimise morbidity, and optimise speech and swallowing function.

Surgical approaches include the following:

- Transoral
 - Electrocautery (Bovie)
 - CO₂ laser
 - Transoral robotic (TORS)
- External
 - Mandibulotomy with mandibular swing
 - Suprahyoid
 - Lateral pharyngotomy

This chapter focusses on surgical management of BOT cancer other than CO₂ laser and TORS.

Surgical Anatomy

The BOT comprises the posterior 1/3 of the tongue behind the **foramen caecum** and **sulcus terminalis** (Figures 1, 2). The mucosa is rough, thick and fixed to the underlying muscle and contains lymphoid follicles (lingual tonsil); this makes it difficult to identify the edges of a BOT tumour; hence frozen section is especially useful to assess resection margins. Postero-laterally the **tonsillolinguual sulcus** separates the tongue from the tonsil fossa. The **valleculae** separate the base of tongue from the lingual surface of the epiglottis and are divided in the midline by the median glossoepiglottic fold. (Figures 1, 2)

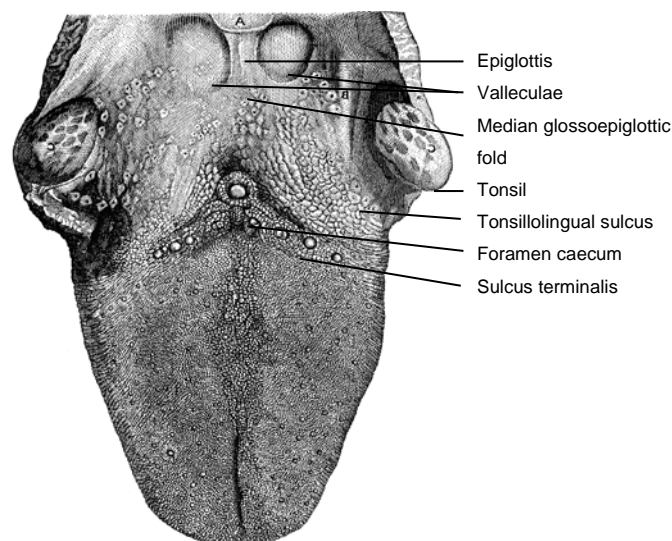


Figure 1: Topography of BOT

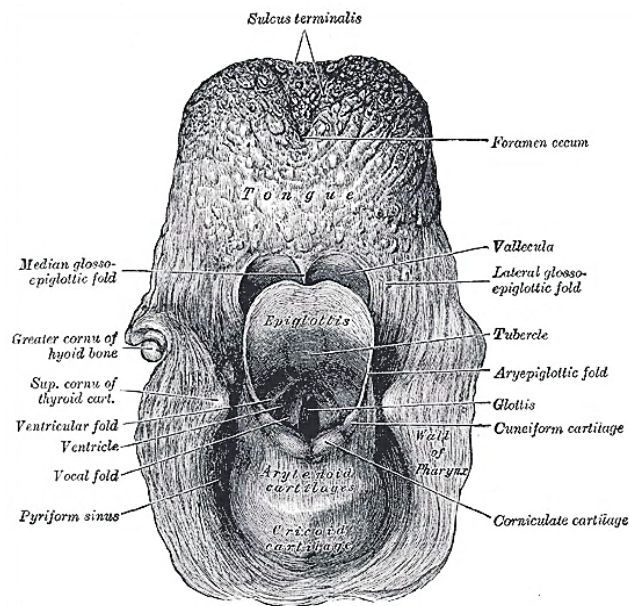


Figure 2: Posterior topographical view of the larynx and BOT

The tongue has **eight muscles**; four **extrinsic** muscles (genioglossus, hyoglossus, styloglossus, palatoglossus) control the position of the tongue and are attached to bone (Figure 3); four **intrinsic** muscles modulate the shape of the tongue, and are not attached to bone. Below the tongue are the **geniohyoid** and **mylohyoid muscles**; the mylohyoid muscle serves as the diaphragm of the mouth and separates the tongue and FOM from the submental and submandibular triangles of the neck (Figures 3, 4).

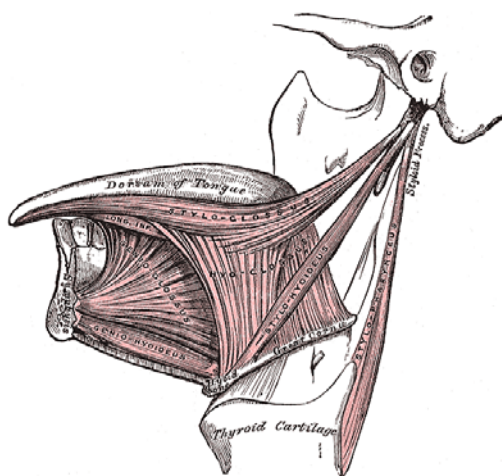


Figure 3: Extrinsic tongue muscles (palatoglossus not shown)

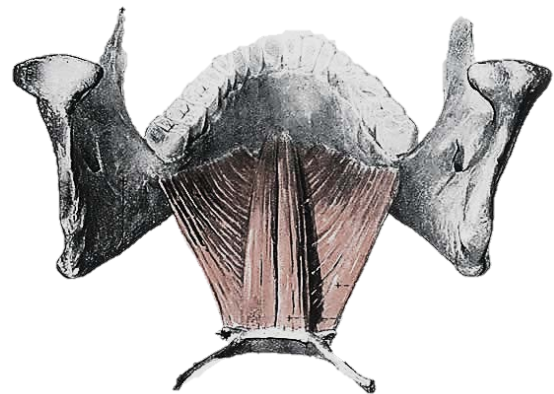


Figure 4: Geniohyoid and mylohyoid muscles

Posteriorly, the **hyoid bone** and **preepiglottic space** are important anatomical structures, an understanding of which is key to assessing whether the larynx can be preserved when using a suprahyoid surgical approach (Figures 5, 6). Most of the **tongue muscles attach to the hyoid bone** (Figures 3, 4); the **lingual artery and hypoglossal nerve (XII)** pass **medial** to the greater cornu of the hyoid (Figures 7, 8). The hyoid bone forms the anterior boundary of the **preepiglottic space**; the superior boundary is the

hyoepiglottic ligament (floor of vallecula), and the posterior border is formed by the petiole of the epiglottis (Figures 5, 6).

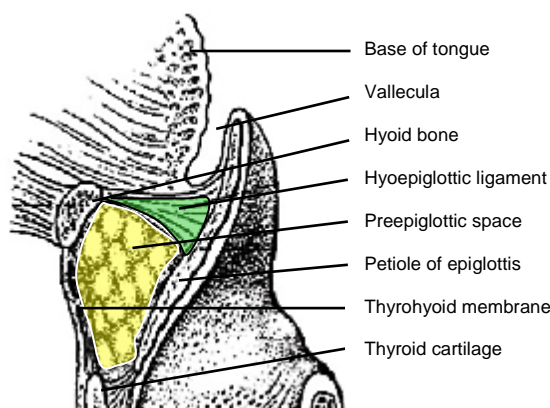


Figure 5: Sagittal view of posterior relations of BOT and preepiglottic space (yellow)

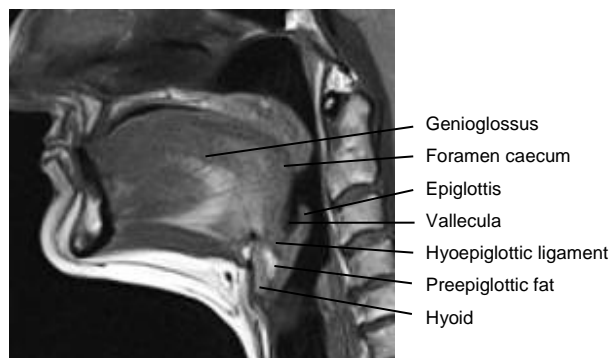


Figure 6: Midline sagittal view of tongue

The **arterial supply** of the BOT is derived from the paired **lingual arteries** and its posterior (*dorsalis linguae*) branches (Figures 7, 8). Additional supply to the BOT emanates from the **tonsillar branch of the facial artery** and the **ascending pharyngeal artery**. In practice the **lingual arteries are the only vessels that have to be looked for** during BOT resection as they are easily injured; it is **important to preserve at least one lingual artery** to avoid infarction of the tongue. (The author has had one case where sacrifice of a single lingual artery led to necrosis of half the tongue; this is however unusual as there is usually adequate cross-flow).

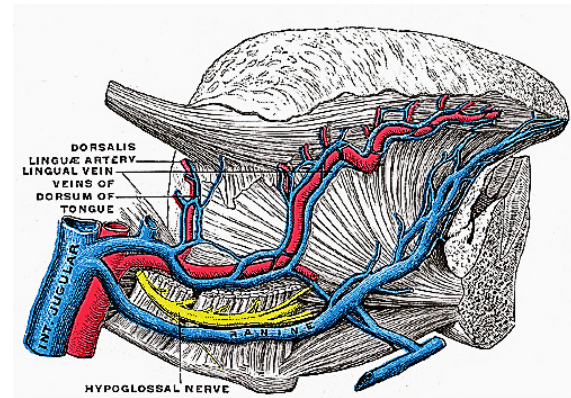


Figure 7: XII n accompanied by the ranine veins

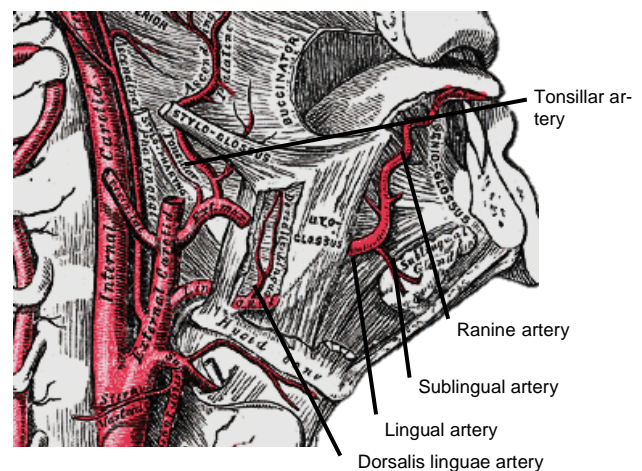


Figure 8: Lingual artery

The **lingual artery** originates from the external carotid artery between the superior thyroid and facial arteries and courses obliquely forwards and medial to the greater cornu of the hyoid (Figures 7, 8). It then loops downward and anteriorly and passes medial to XII n and the stylohyoid muscle. It then courses directly anteriorly and deep to the hyoglossus and finally ascends submucosally on the undersurface of the tongue as far as its tip as the **ranine artery** (*profunda linguae*); it lies to either side of the genioglossus, and is accompanied by the lingual nerve. Two or three small **dorsalis linguae** arteries arise beneath the hyoglossus and ascend to the posterior part of the dorsum of the tongue and also supply the mucous membrane of the posterior floor of mouth (FOM) and oropharynx (Figures 7, 8).

Venous drainage is via **lingual** and **ranine veins** (Figure 7). The **lingual veins** originate on the dorsum, sides, and under-surface of the tongue and accompany the lingual artery and join the internal jugular vein. The **ranine veins** originate below the tip of the tongue and are visible on its ventral surface; they accompany the XIIⁿ as *venae comitantes* and either join the lingual vein or pass lateral to hyoglossus to join the common facial vein.

An understanding of the **nerve supply** is important to preserve oral function. All intrinsic and extrinsic muscles are innervated by the XIIⁿ except for palatoglossus which is innervated by Xⁿ. The IXⁿ provides somatic afferent and taste sensation to the posterior 1/3 of the tongue. The **lingual nerve** provides general somatic sensation to the anterior 2/3 of the mouth and FOM; taste is provided by the chorda tympani branch of VIIⁿ via the lingual nerve.

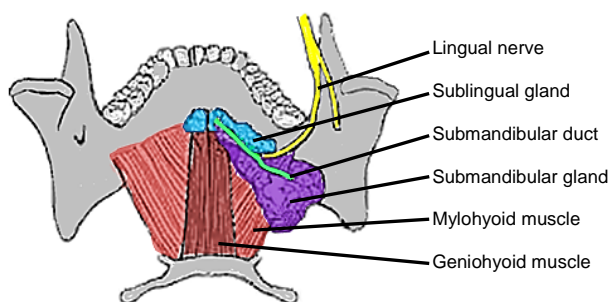


Figure 9: Superior view of FOM, sub-mandibular gland and duct, lingual nerve and mylohyoid and geniohyoid muscles

The lingual nerve is at risk when using a mandibular swing approach to resect tumours of the BOT. The nerve crosses deep to the submandibular duct in the lateral FOM; in the anterior FOM it is located posterior to the duct (Figures 9, 10).

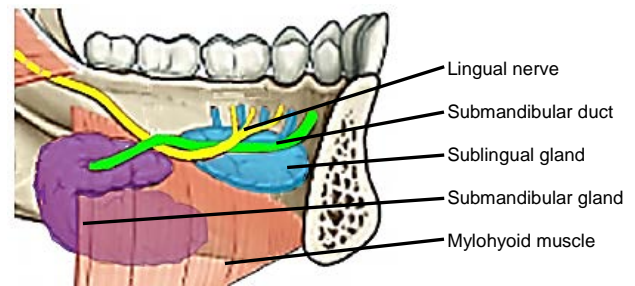


Figure 10: Intraoral view of left sublingual gland with ducts of Rivinus, submandibular gland and duct, lingual nerve and mylohyoid muscles

The remainder of this chapter focuses on surgical resection of cancers of the BOT.

Surgical Objectives

- Adequate tumour **resection margins**; this requires a surgical approach that permits good exposure
- **Surgical morbidity** should be kept to a minimum relating to swallowing, aspiration, speech, mandibulotomy, lingual nerve function and voice (laryngectomy is required in selected cases to avoid aspiration)
- **Control occult cervical metastasis; both sides of the neck are electively treated** because of a significant risk of having bilateral occult cervical metastases; the author generally does bilateral elective neck dissection (END) levels I-IV for squamous cell carcinoma of the BOT

Key surgical points

- **Oral or transnasal intubation** may be difficult or impossible
- Select a surgical approach(es) that ensures **adequate exposure**; transoral access is often inadequate
- The surface of the BOT is firm and irregular making it difficult to determine margins; employ **frozen section** to control resection margins
- **Preserve tongue function**

- **Preserve at least one XIIIn**; sacrificing both nerves is crippling from speech and swallowing perspectives
- **Preserve at least one lingual artery** to avoid infarction of the tongue
- Preserve **sensation** with the mandibular swing approach by preserving the lingual nerve
- **Avoid/minimise aspiration**; this may necessitate total laryngectomy in selected cases.

Preoperative evaluation

1. **Are there synchronous primaries, cervical or distant metastases?** CXR or CT chest, and panendoscopy.
2. **Is the tumour resectable?** BOT cancer may be irresectable if it invades the parapharyngeal space and carotid sheath, or extends anteriorly to necessitate total glossectomy in patients not prepared to undergo such surgery. It may be difficult to assess the extent of the primary due to pain, tenderness or trismus. If in doubt, a patient requires imaging such as CT/MRI, or examination under anaesthesia.
3. **Is laryngectomy required?** Invasion of the preepiglottic space or epiglottis generally indicates a need for laryngectomy to permit swallowing without aspiration (Figure 11).

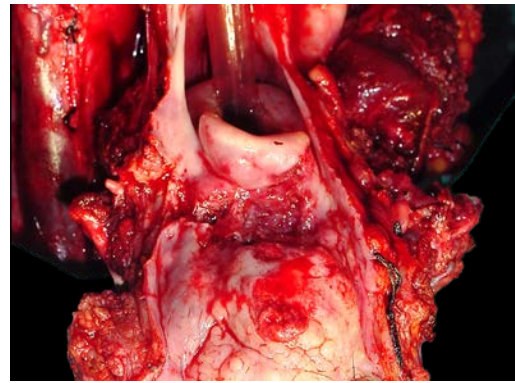


Figure 11: BOT cancer invading vallecula, preepiglottic space and epiglottis and requiring total laryngectomy

Invasion of the preepiglottic space is best assessed with MRI / CT scan in a sagittal plane (Figure 12).

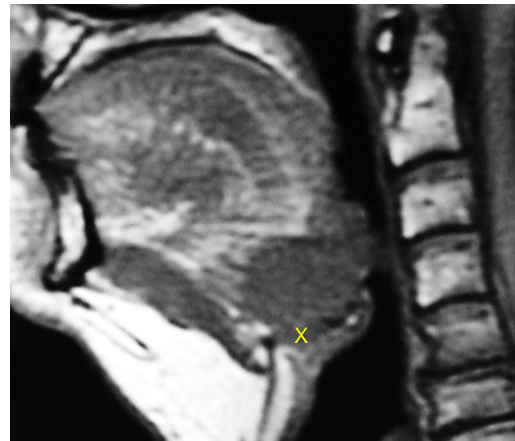


Figure 12: BOT cancer invading and replacing the preepiglottic space (x)

Invasion of the pre-epiglottic space can also be assessed intraoperatively by palpating the pre-epiglottic space between a finger placed in the vallecula and a finger placed on the skin of the neck just above/below the hyoid bone; fullness is indicative of tumour in the pre-epiglottic space (Figure 13).

4. **Is reconstruction required?** Restoring BOT bulk with soft tissue flaps may improve speech; however, having an insensate flap **may impair swallowing**. Therefore filling the defect with a flap should only be done in selected cases.

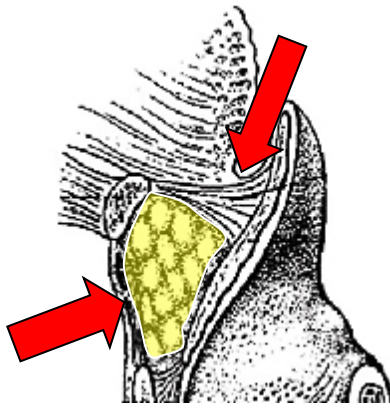


Figure 13: Digital palpation for involvement of pre-epiglottic space

5. **Can the patient tolerate aspiration?** Physical fitness, pulmonary reserve, and cognitive function should be considered when selecting patients for major resections and reconstructions as such surgery may be complicated by a variable measure dysphagia and aspiration, especially if followed by chemo-radiation.
6. **Status of dentition?** Carious teeth should be removed at the time of the surgery to avoid osteoradionecrosis.
7. **Is a tracheostomy required?** Almost all patients require temporary tracheostomy.

Anaesthesia

The **surgeon always stands by the patient during induction** of anaesthesia as it may be **difficult or impossible to intubate** a patient with a bulky BOT tumour that precludes elevation of the tongue to visualise the larynx. Should the anaesthetist be unable to intubate the larynx, the surgeon may be able to intubate with a laryngo-scope, or do an emergency tracheostomy or cricothyroidotomy; it is prudent to inject the tracheostomy or cricothyroidotomy site with local

anaesthetic with adrenaline prior to induction. Nasal intubation facilitates resection of BOT tumours, and is converted to a tracheostomy during the course of the operation.

Perioperative antibiotics are prescribed for 24hrs.

Surgical access

Good surgical access is essential in order to attain adequate resection margins, to control bleeding, and for reconstruction. A combination of open surgical approaches can be used, and will now be discussed. **Level 1 of the neck should first be dissected** if neck dissection is indicated before proceeding to address the primary tumour.

Transoral access with electrocautery (Bovie) resection

The adequacy of transoral access to the BOT varies considerably. A useful way to predict whether transoral resection is likely to be possible is to pull on the anterior tongue with a cotton swab during pre-operative clinical evaluation and to then see how accessible the tumour is. Note that **tumours becomes more visible and accessible as the resection proceeds**, especially once the thick BOT lining has been incised around the tumour. Laterally placed BOT cancers, especially in edentulous patients, are more amenable to trans-oral access (Figure 14).

The mouth is kept wide open either with a dental bite block (Figure 15) or with a self-retaining retractor, taking care to protect the teeth from injury (Figure 16). Apply traction to tongue and tumour with silk traction sutures or with tissue forceps (Figure 16).

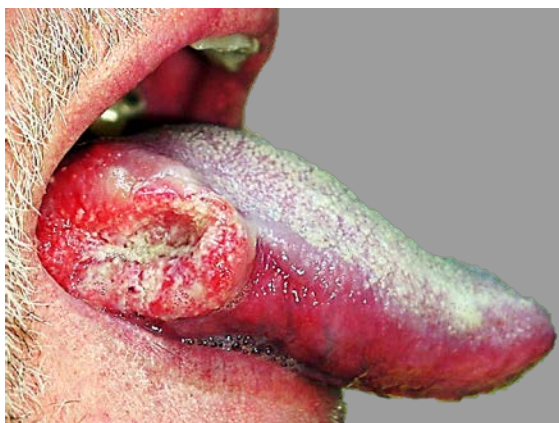

Figure 14: Laterally located BOT cancer suited to transoral resection <http://www.tobaccofacts.info/images/20071112-oral-cancer.jpg>

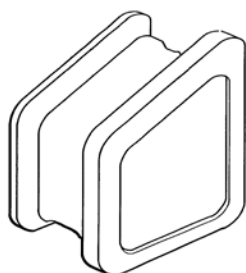


Figure 15: Dental bite block is interposed between lateral teeth to keep mouth open

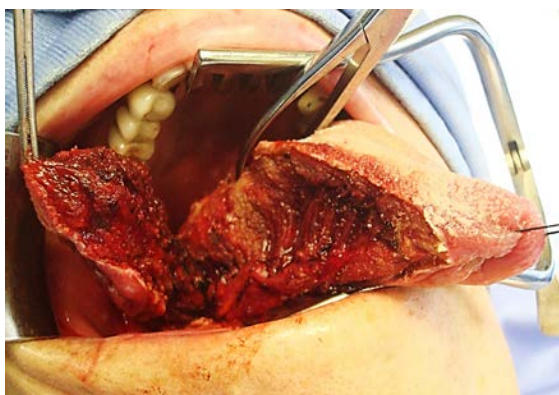


Figure 16: Self-retaining retractor; lateral oral and BOT tumour being resected

Resect the tumour with at least a 1cm margin of normal tissue using electrocautery (Bovie). As the resection proceeds posteriorly, insert new silk traction sutures or move the tissue forceps more posteriorly to facilitate delivery of the tumour into the mouth.

Transoral access with median glossotomy

Midline BOT tumours may be exposed by bisecting the tongue along the median raphe with electrocautery (Figure 17); it is a relatively avascular plane as the vessels and nerves all course laterally, and results in little, if any, functional deficits. The incision can be carried posteriorly up to the hyoid bone if needed.

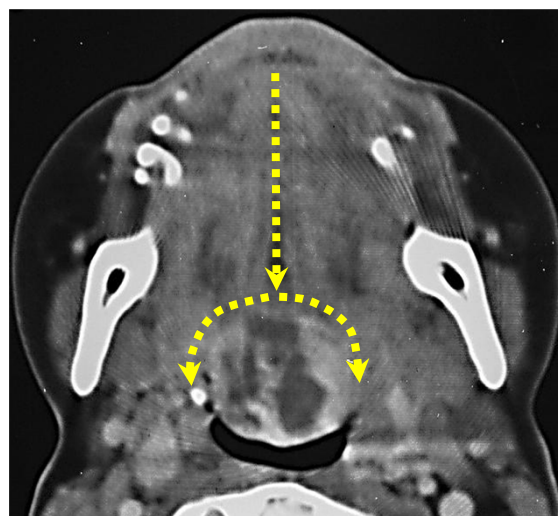


Figure 17: Median glossotomy for lingual thyroid

Mandibulotomy with mandibular swing

This affords excellent access to the BOT. It is especially well suited to cancers that extend anteriorly to involve the oral tongue (Figure 14), or onto the soft palate. It does however leave a facial scar; it may cause deformity of the lower lip; there is a risk of complications relating to the mandibulotomy and dental malocclusion; and the lingual nerve is at risk of injury.

The vermillion border is scored or marked so as to ensure an accurate repair (Figure 18). The lower lip is divided vertically in the midline (Figure 19). Bleeding from the labial artery is controlled with cautery. Incise the gingivolabial and gingivobuccal mucosae >0.5cms from the bone leaving a cuff of

soft tissue on the bone to facilitate subsequent soft tissue closure (*Figure 20*). Strip soft tissue off the mandible with monopolar cautery or with a periosteal elevator up to the mental foramen, taking care not to injure the mental nerve where it exits the foramen (*Figure 20*).

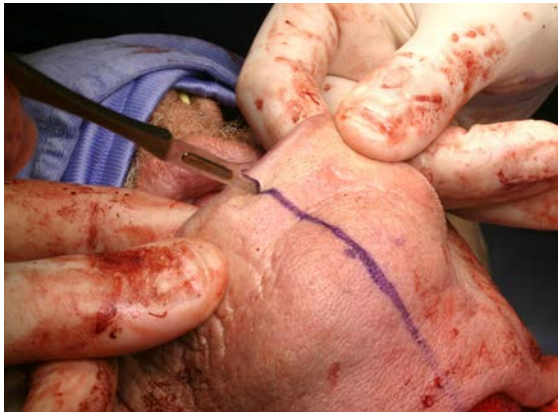

Figure 18: Scoring vermilion border for accurate closure

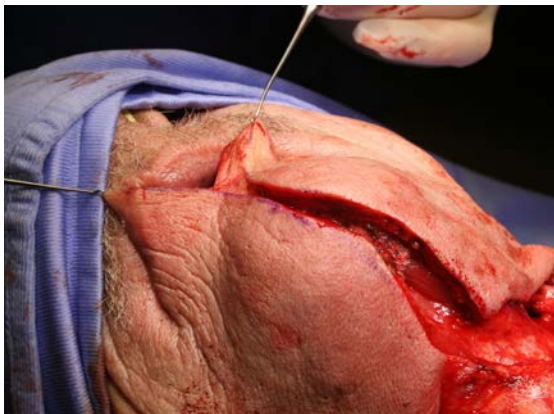


Figure 19: Lip-split incision down to bone

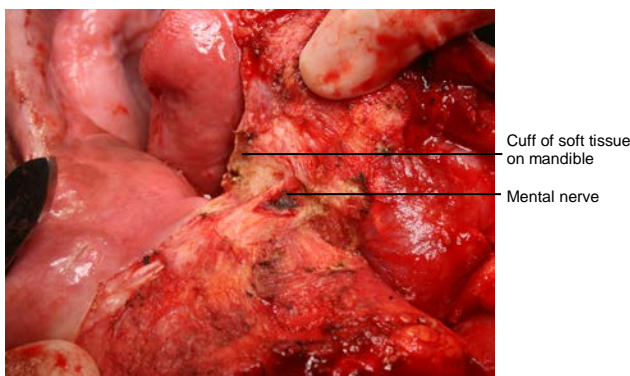


Figure 20: Note preserved mental nerve and cuff of soft tissue

saw (*Figure 21*). The osteotomy may be made vertically or alternatively in a step- or V-shaped fashion so as to achieve a more stable repair (*Figure 22*). It is advisable to extract a tooth and make the osteotomy through the dental socket so as to avoid devitalising adjacent teeth. In dentate patients the mandible is preplated with titanium miniplates contoured to the mandible so as to ensure perfect dental alignment. Two 4-holed, non-compression, 2mm mandibular plates, one placed along the inferior border of the mandible, and the other placed more superiorly are used. Once the plates have been contoured and the holes drilled, they are removed and the bone cut is made.



Figure 21: Gigli saw

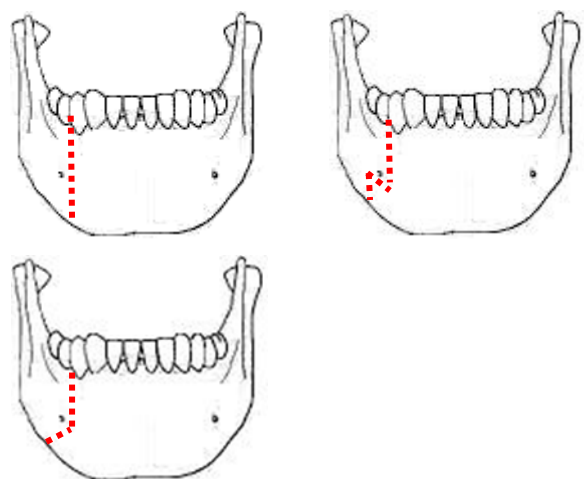


Figure 22: Examples of osteotomies

The mandible is divided just anterior to the mental foramen with a Gigli or a powered

The surgeon then distracts the cut ends of the mandible to gain access to the oral cavity and proceeds to divide the floor of mouth (FOM) mucosa and mylohyoid muscle about 1cm from, and parallel to, the mandible, so as to leave soft tissue on the mandible for the subsequent FOM repair at conclusion of surgery. Continue the incision posteriorly along the FOM until the tumour comes into view; the lingual artery (medial to the hyoglossus muscle) and the XIIIn course medial to the FOM incision are not at risk of injury at this stage of the dissection. The tumour is resected using electrocautery. The lingual artery may have to be ligated (Figure 23).

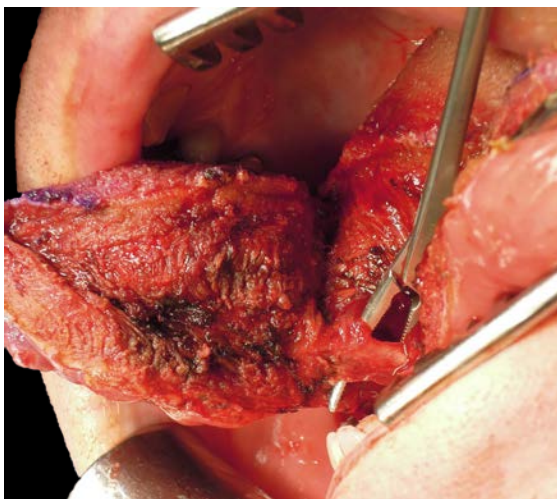


Figure 23: Lingual artery

Posteriorly the **lingual nerve** extends from the skull base and crosses the line of the incision from lateral to medial to course along the lateral FOM; preserve the nerve if possible (Figure 24).

At conclusion of surgery the FOM is closed with a running vicryl suture, and the osteotomy is plated; when plating sets are not available, opposing holes are drilled on either side of the osteotomy and the mandible is wired together with stainless steel wiring (Figure 25). The lip is carefully repaired in

layers to approximate the muscles as well as mucosa and skin.

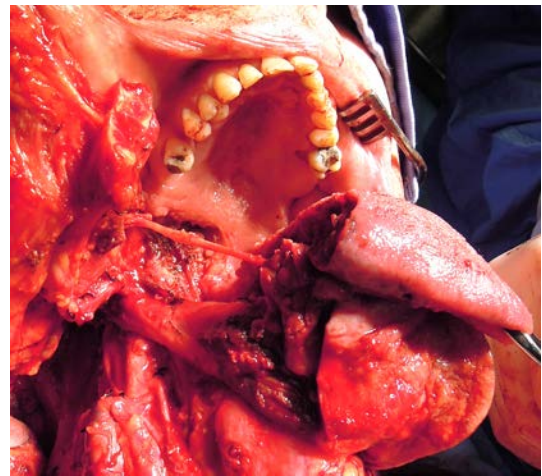

Figure 24: Note wide exposure afforded by mandibulotomy approach to the base of tongue and oropharynx, and the preserved lingual nerve crossing the surgical field

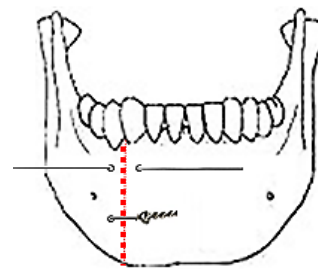


Figure 25: Mandible wired together with stainless steel wire

Suprahyoid approach

This is one of the external approaches favoured by the author. It is similar to the suprahyoid dissection step during total laryngectomy. It is well suited to most BOT cancers (Figure 26), although access is limited with cancers that extend far anteriorly into the tongue.

Because the pharynx is entered through the vallecula, it is **not suited to** cancers that involve the apex of the vallecula, preepiglottic space or epiglottis (Figure 11). **Following completion of Levels 1a and b of the neck dissection(s)**, the superior aspect of the body of the hyoid bone is skeletonised with

electrocautery, keeping the dissection between the lesser cornua of the hyoid bone. The dissection is carried posteriorly above the hyoepiglottic ligament, which forms the roof of the preepiglottic fat (*Figure 27*). The vallecula is entered at its apex (*Figure 27*).

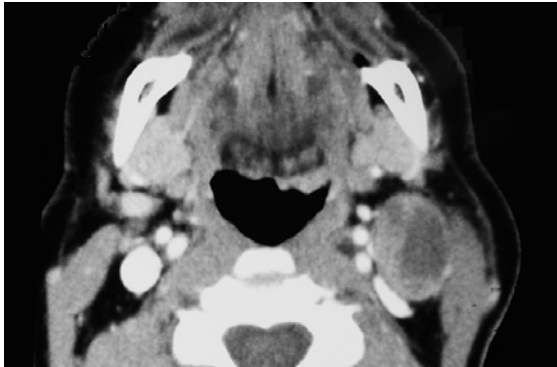


Figure 26: BOT cancer with cystic metastasis suited to suprahyoid approach

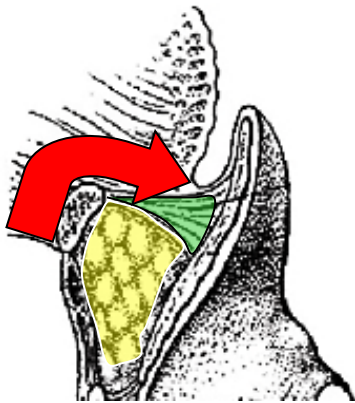


Figure 27: Red arrow indicates suprahyoid access to BOT (hyoepiglottic ligament coloured green)

The tumour now comes into view. The cancer is resected with electrocautery (*Figures 28-30*). Take care to identify and preserve the **lingual arteries** and, if dissecting even more laterally, the **XIIIn** (*Figures 29, 30*). Tumour exposure improves as the thick BOT lining is incised to either side of the tumour making the tumour more mobile (*Figure 30*).

Orientate the specimen for the pathologist with a suture before removing the specimen so as not to lose orientation. The adequacy

of the resection margins is checked with frozen section if available.

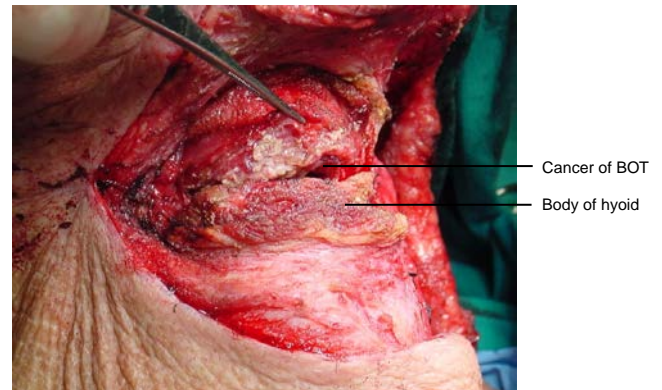


Figure 28: Initial entry into vallecula

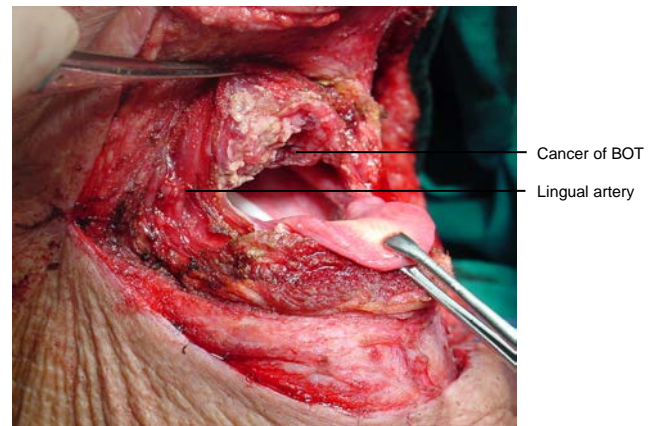


Figure 29: Note wide access to epiglottis, BOT and posterior wall of pharynx

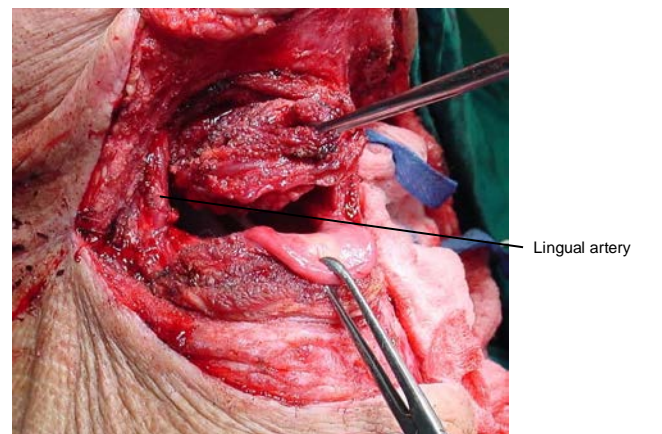


Figure 30: Note wide access to epiglottis

Primary closure can almost always be done by approximating the BOT resection margin to the vallecula with a running vicryl suture. The supra- and infrahyoid muscles are then sutured together and the neck is closed in the usual fashion.

A **temporary tracheostomy** is done and a nasogastric feeding tube is inserted. Once the airway appears adequate the tracheostomy tube is corked for 24hrs before being removed.

Lateral pharyngotomy combined with suprahyoid approach

Additional exposure can be obtained by extending the incision along the greater cornu of the hyoid bone and along the posterior margin of the thyroid cartilage; take special care to identify and not to injure the XIIIn, the lingual artery or the superior laryngeal nerve (*Figure 31*).

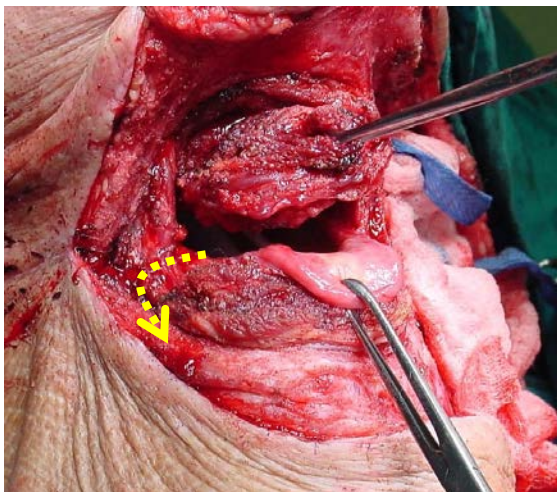


Figure 31: Additional access by lateral pharyngotomy extension (Yellow arrow)

Pull-through approach

This may be employed when tumour stops some distance from the inner aspect of the mandible. The mucosa of the lateral and anterior FOM is divided >0.5cm from the inner aspect of the mandible (so as to facilitate later repair), taking care not to injure the lingual and XIIIn, or the submandibular ducts. Following bilateral neck dissections of Levels 1a and 1b, the mandibular attachments of the anterior bellies of digastric, mylohyoid, geniohyoids and genioglossus

are divided with electrocautery working from inferiorly (*Figure 32*). This permits the surgeon to drop the FOM and tongue into the neck and to proceed with the resection. At conclusion of surgery the FOM mucosa and muscle are reapproximated with vicryl sutures.

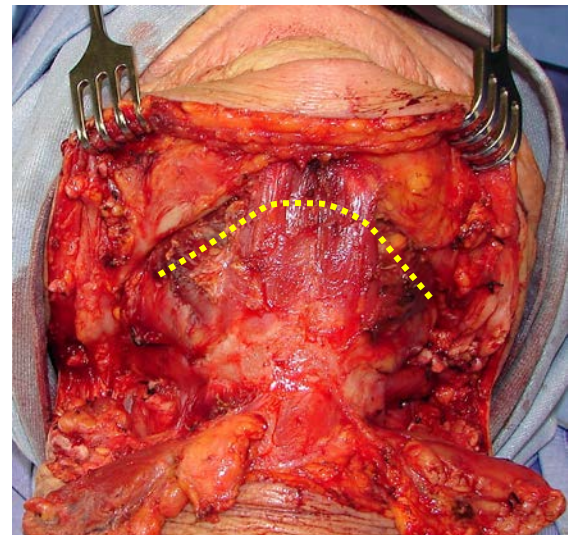


Figure 32: Incision for pull-through approach (Yellow line)

Repair / Reconstruction

Obtain **meticulous haemostasis** using ties, monopolar and bipolar cautery before closing the defect. Primary closure of BOT defects gives the best swallowing function although inadequate bulk impairs speech if the BOT cannot approximate the soft palate. Simply shaping a flap to match the resected tissue may well restore form but may have a poor functional result. Therefore one has to carefully assess the defect to determine how best to optimise swallowing and speech.

Radial free forearm flap: This is a thin and pliable flap and preserves mobility of the tongue, but has limited bulk.

Anterolateral free thigh flap: Muscle harvested with the flap can be tailored to conform to the volume of the defect to be filled. However it is less pliable than the radial free forearm flap and is only suitable for oral reconstruction in patients with thin thighs.

Pectoralis major flap: This is a good option to use (See chapter: [Pectoralis major flap](#))

Buccinator flap: A posteriorly based buccinator flap can be used to close a small orocervical communication following resection of a lateral BOT cancer. (See chapter: [Buccinator myomucosal flap](#))

Final comments

Resecting tumours of the BOT is challenging particularly in terms of access and maintaining swallowing function. One should not compromise resection margins for function. The surgical team has to master an array of surgical approaches and reconstructive techniques so as to ensure the best oncological and functional outcomes.

Author & Editor

Johan Fagan MBChB, FCORL, MMed
Professor and Chairman
Division of Otolaryngology
University of Cape Town
Cape Town, South Africa
johannes.fagan@uct.ac.za