

# PAROTIDECTOMY

Johan Fagan

The facial nerve is central to parotid surgery for both surgeon and patient. Knowledge of the surgical anatomy and the landmarks to find the facial nerve are the key to preserving facial nerve function.

## Surgical Anatomy

### Parotid gland

The parotid glands are situated anteriorly and inferiorly to the ear. They overlie the vertical mandibular rami and masseter muscles, behind which they extend into the retromandibular sulci. The glands extend superiorly from the zygomatic arches and inferiorly to below the angles of the mandible where they overlie the posterior bellies of the digastric and the sternocleidomastoid muscles. The parotid duct exits the gland anteriorly, crosses the masseter muscle, curves medially around its anterior margin, pierces the buccinator muscle, and enters the mouth opposite the 2<sup>nd</sup> upper molar tooth.

### Superficial Muscular Aponeurotic System and Parotid Fascia

The **Superficial Muscular Aponeurotic System (SMAS)** is a fibrous network that invests the facial muscles, and connects them with the dermis. It is continuous with the platysma inferiorly; superiorly it attaches to the zygomatic arch. In the lower face, the facial nerve courses deep to the SMAS and the platysma. The parotid glands are contained within two layers of **parotid fascia**, which extend from the zygoma above and continue as cervical fascia below.

### Structures that traverse, or are found within the parotid gland

- **Facial nerve and branches** (Figure 1)
- **External carotid artery:** It gives off the **transverse facial artery** inside the gland before dividing into the internal maxillary and the superficial temporal arteries (Figure 2)

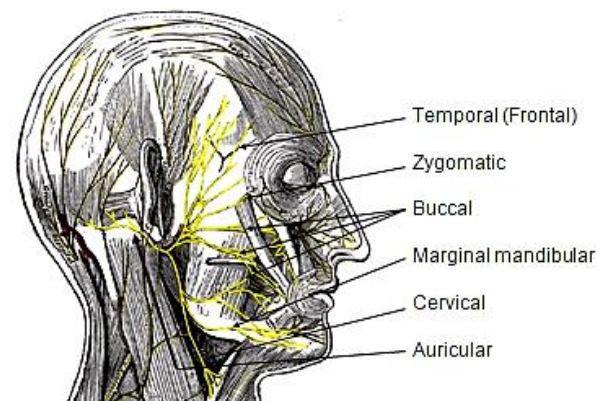


Figure 1: Main branches of facial nerve

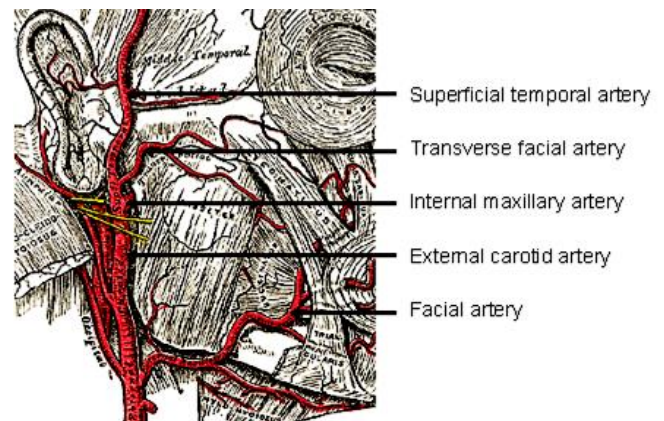


Figure 2: Branches of external carotid artery

- **Veins:** The **maxillary** and **superficial temporal veins** merge into the retro-mandibular vein within the parotid gland, but are not responsible for draining the gland. Venous drainage of the parotid itself is to tributaries of external and internal jugular veins.

- **Lymphatics:** A number of lymph nodes are present within the gland, principally in the superficial lobe, and drain to Level 2 of the neck.

### Relevant surgical relations

**Posterior:** Cartilage of external auditory meatus; tympanic bone, mastoid process, sternocleidomastoid muscle

**Deep:** Styloid process, stylomandibular tunnel, parapharyngeal space, posterior belly of digastric, sternocleidomastoid muscle

**Superior:** Zygomatic arch, temporomandibular joint

### Facial nerve

The facial nerve exits the stylomastoid foramen, and enters the parotid gland. Although the branching pattern does vary from patient to patient, the trunk generally divides at the *pes anserinus* into upper and lower divisions that subsequently branch into temporal (frontal), zygomatic, buccal, marginal mandibular and cervical branches that innervate the muscles of facial expression. Small branches to the posterior belly of digastric, stylohyoid, and auricular muscles also arise from the trunk (Figure 3).

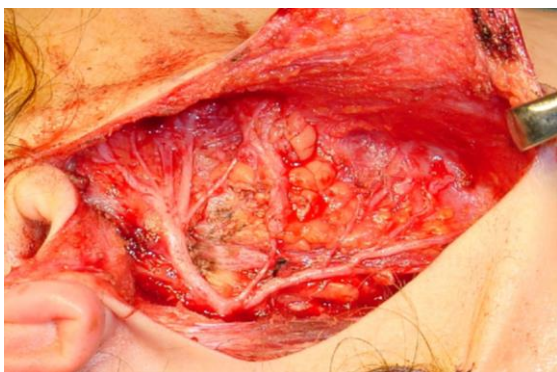


Figure 3: The facial nerve trunk dividing into superior and inferior divisions at the *pes anserinus*

The nerve traverses the parotid gland, with about 2/3 of the gland substance being superficial to the nerve. As parotid dissection generally is directed along the facial nerve, the nerve in effect divides the parotid from a surgical perspective into superficial and deep lobes, although there is no natural soft tissue dissection plane that separates the two lobes.

The midfacial nerve branches have multiple cross-innervations; however the frontal and marginal mandibular branches do not have cross-innervations and injury to these branches is followed by paralysis of the forehead and depressors of the lower lip (Figure 4). Therefore unlike the temporal and marginal mandibular nerves, selected midfacial branches may be sacrificed without loss of facial function.

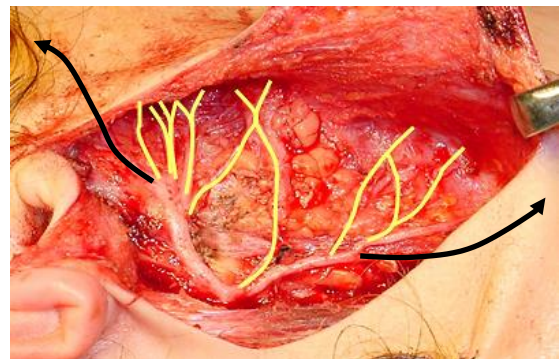


Figure 4: Midfacial branches (yellow) interconnect whereas temporal and marginal mandibular (black) do not

### Locating the Facial Nerve

It is useful to know preoperatively whether a parotid tumour is situated deep or superficial to the facial nerve. This facilitates surgical planning and facilitates preoperative consent relating to the likelihood of a temporary postoperative facial nerve weakness.



## Surface markings

**Facial nerve trunk:** The trunk exits the skull at the stylomastoid foramen. This is situated at the deep end of the tympanomastoid suture line, which can be located at the junction between the mastoid process and the tympanic ring of the external ear canal

**Temporal (frontal) branch of facial nerve:** The nerve crosses the zygomatic arch; it runs within the SMAS and lies superficial to the deep temporalis fascia. It courses more or less along a line drawn between the attachment of the lobule of the ear to a point 1.5 cm above the lateral aspect of the eyebrow. To avoid injury to the temporal branch dissect either in a subcutaneous plane or deep to the SMAS (Figure 1).

## Radiology

Radiological investigation is not routinely required with parotid tumours. It is recommended for surgical planning with tumours that are large, fixed, and are associated with facial nerve involvement, trismus, and parapharyngeal space involvement. MRI is a valuable investigation with recurrence of pleomorphic adenoma as it is often multifocal.

The extratemporal facial nerve is not visible with ultrasound, CT or MRI. The retromandibular vein is however intimately associated with the facial nerve. The vein courses through the parotid gland immediately deep to the facial nerve, but rarely runs immediately superficial to the nerve (Figures 5 & 6). Reliance is therefore placed on the juxtaposition of the retro-mandibular vein and the nerve to predict whether a tumour is likely to be deep or superficial to the nerve.

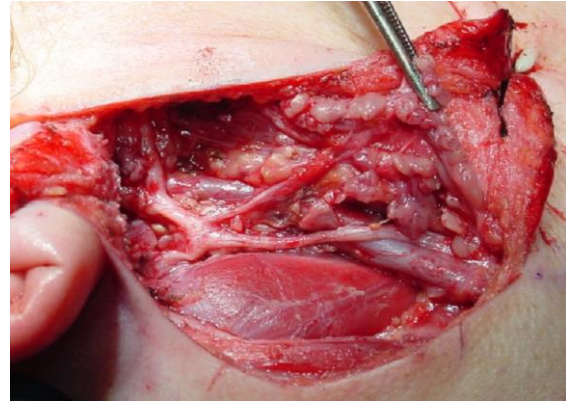


Figure 5: Facial nerve running superficial to retromandibular vein

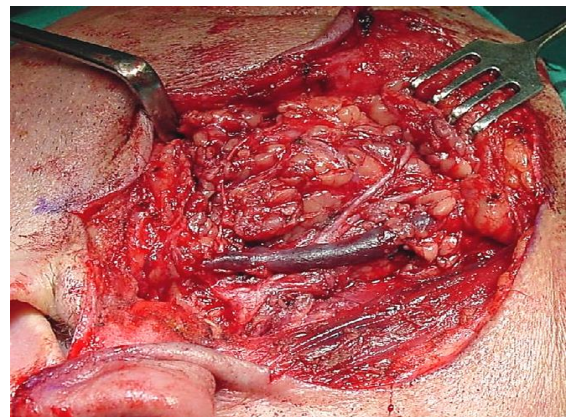


Figure 6: Facial nerve running deep, but close, to retromandibular vein

The retromandibular vein can be clearly visualized on a CT with contrast, or an MRI (Figures 7, 8).

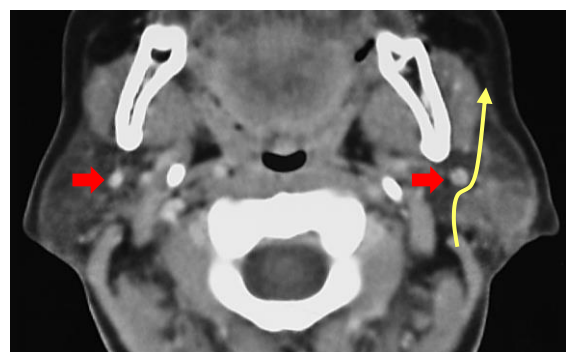


Figure 7: Red arrows indicate retromandibular veins, and yellow arrow the course of the facial nerve in a superficial lobe pleomorphic adenoma

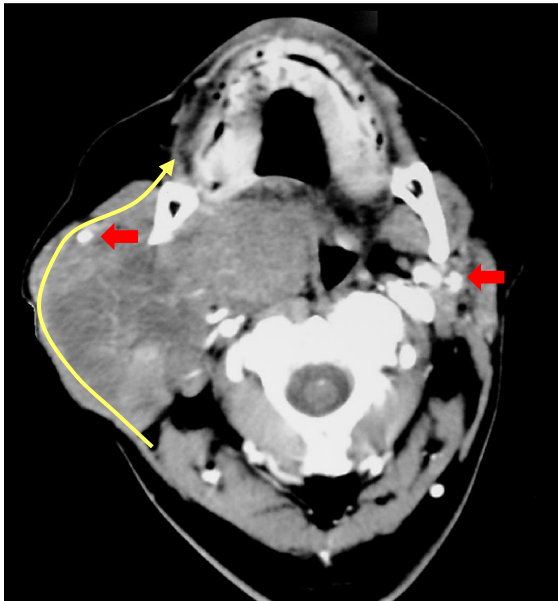


Figure 8: Red arrows indicate retro-mandibular veins, and yellow arrow the course of the facial nerve in a deep lobe pleomorphic adenoma

Radiology may also alert the surgeon to extension of a deep lobe parotid tumour through the stylomandibular tunnel into the parapharyngeal space (Figure 9).

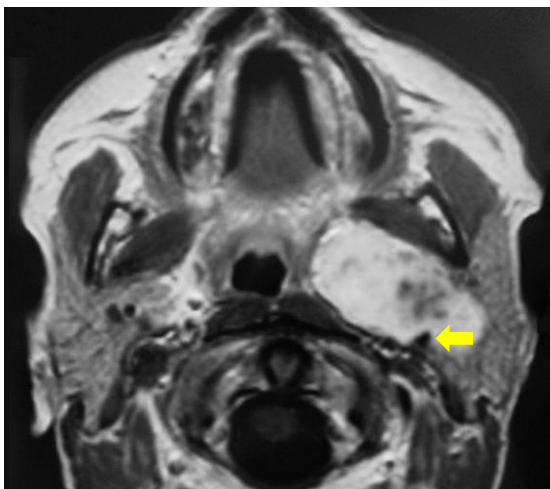


Figure 9: Tumour passing through stylomandibular tunnel to parapharyngeal space (Arrow indicates styloid process)

### ***Intraoperative location of facial nerve***

The facial nerve is usually explored by prograde dissection *i.e.* by locating the nerve trunk where it exits from the stylomastoid foramen, and then dissecting anteriorly along the trunk, the *pes anserinus* and the

divisions and nerve branches. Occasionally this is not possible *e.g.* with a large fixed mass centered at the stylomastoid foramen. In such cases a retro-grade dissection may be required after locating the temporal branch where it crosses the zygoma, the buccal branches which lie parallel to the parotid duct (Figure 10), or the marginal mandibular branch where it crosses the facial artery and vein just below or at the inferior margin of the mandible, where it is just deep to platysma (Figure 11).

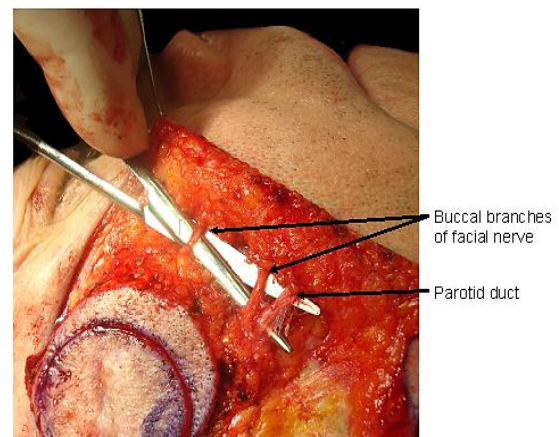


Figure 10: Buccal branches adjacent to the parotid duct

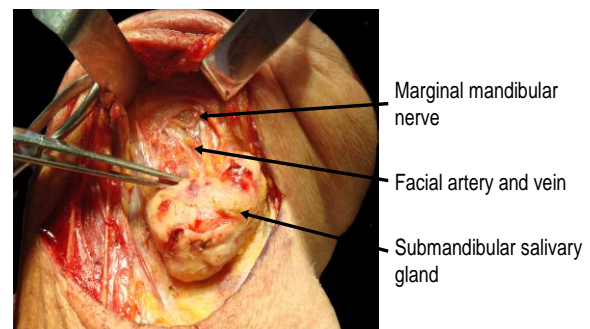


Figure 11: Marginal mandibular nerve crossing facial artery and vein

The surgical landmarks for finding the facial nerve trunk at the stylomastoid foramen are remarkably constant, and all the landmarks should be identified at every operation to facilitate finding the nerve (Figures 12, 13).



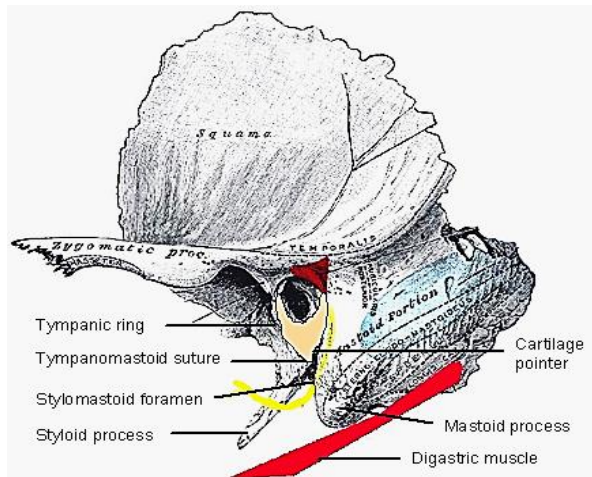


Figure 12: Schematic surgical landmarks for the facial nerve trunk

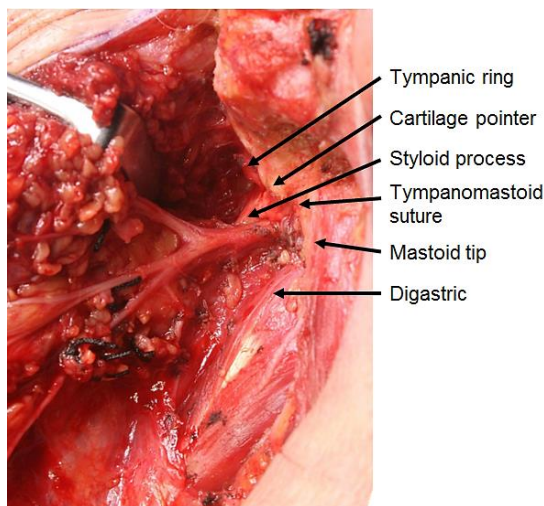


Figure 13: Intraoperative surgical landmarks for the facial nerve trunk

**Posterior belly of digastric muscle:** The nerve runs at the same depth below the skin surface, and bisects the angle between the muscle and the styloid process

**Cartilage pointer:** This refers to the medial-most, pointed end of the cartilage of the external auditory meatus. The nerve exits the foramen approximately 1cm deep and 1cm inferior to this point

**Tympanic ring, mastoid process and tympanomastoid suture line:** The tympanomastoid suture line is the most precise landmark for the facial nerve as it leads medially, directly to the stylomastoid foramen

**Styloid process:** The facial nerve crosses the styloid process. Palpating the styloid process is therefore a useful means to determine the depth and position of the facial nerve

**Branch of occipital artery:** A small branch of the occipital artery is commonly encountered just lateral to the facial nerve close to the stylomastoid foramen. Brisk arterial bleeding should therefore alert the surgeon to the proximity of the facial nerve; it is easily controlled with bipolar cautery.

### **Electrical stimulation and monitoring**

These need not be routinely employed, but may be useful adjuncts to a sound knowledge of facial nerve anatomy in selected cases such as revision surgery and with large tumours. It may however not record facial stimulation with faulty equipment, and nerve fatigue following excessive mechanical or electrical stimulation, and use of a muscle relaxant.

- **Electrophysiological monitoring:** An EMG monitor may be used to detect contraction of the facial muscles when the facial nerve is mechanically or electrically stimulated.
- **Facial nerve electrical stimulation:** Battery operated or more sophisticated nerve stimulators may be employed intraoperatively to assist with finding the nerve, or to differentiate between nerve and blood vessels. Stimulating the nerve produces visible contraction of the facial musculature or an EMG signal.

### **Types of Parotidectomy**

- **Partial parotidectomy:** Resection of parotid pathology with a margin of nor-

mal parotid tissue. This is the standard operation for benign pathology and favourable malignancies

- **Superficial parotidectomy:** Resection of the entire superficial lobe of parotid (Figure 3) and is generally used for metastases to parotid lymph nodes e.g. from skin cancers, and for high grade malignant parotid tumours.
- **Total parotidectomy:** This involves resection of the entire parotid gland, usually with preservation of the facial nerve

### Preoperative consent

**Scar:** Usually very good healing except over the mastoid where some scarring may occur

- **Anaesthesia in the greater auricular distribution:** Skin of inferior part of auricle, and overlying the angle of the mandible
- **Facial nerve weakness:** Temporary weakness common (<50%); permanent weakness rare
- **Facial contour:** loss of parotid tissue leads to a more defined angle of mandible, and deepening of retromandibular sulcus
- **Prominence of auricle:** This is probably due to loss of innervation of the postauricular muscles and preauricular scarring
- **Frey's syndrome (gustatory sweating):** Although common, it only very rarely is bad enough to require treatment with Botox injection

### Anaesthesia

- General anaesthesia

- Short-acting muscle relaxation for intubation only, so that facial nerve may be stimulated and/or monitored
- No perioperative antibiotics unless specifically indicated
- Hyperextend the head, and turn to opposite side
- Infiltrate with vasoconstrictor along planned skin incision, so as to reduce thermal injury to skin from electro-cautery to skin vessels
- Keep corner of eye and mouth exposed so as to be able to see facial movement when facial nerve mechanically or electrically stimulated (Figure 14)

### Partial/Superficial Parotidectomy

- **Lazy-S incision:** This is placed in pre-auricular and cervical skin creases (Figure 14)

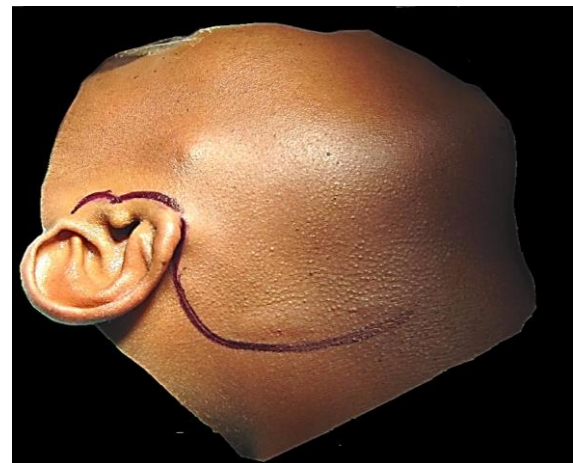

Figure 14: "Lazy-S" incision; Corners of eye and mouth exposed

- Raise superficial cervicofacial flap to the anterior border of parotid mass or of the parotid gland in the plane between the SMAS and the parotid fascia with a scalpel or diathermy. The assistant must monitor the face for muscle contraction to avoid facial nerve injury. Insert a traction suture in the subcutaneous tissue of the ear lobule as well as securing

the anterior based skin flap to the drapes (Figure 15)

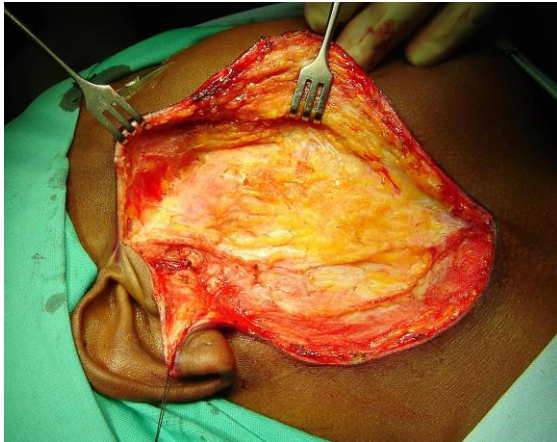


Figure 15: Exposure of parotid mass or gland

- Skeletonise the anterior border of sternocleidomastoid muscle (Figure 16)
- Divide the external jugular vein
- Divide the greater auricular nerve as it crosses sternocleidomastoid muscle, posterior to the external jugular vein. An attempt can be made to preserve the posterior branch of the nerve to retain sensation of the skin of the auricle (Figure 17)

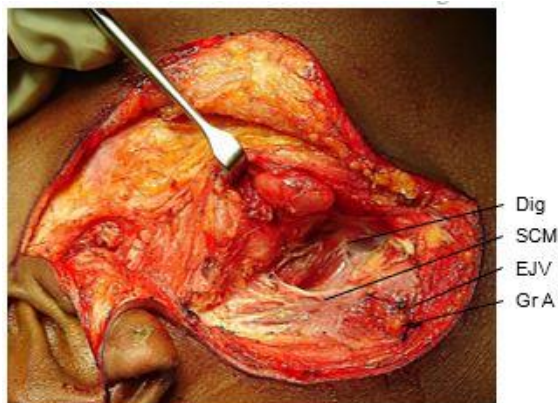

Figure 16: Expose the sternomastoid and posterior belly of digastric muscle

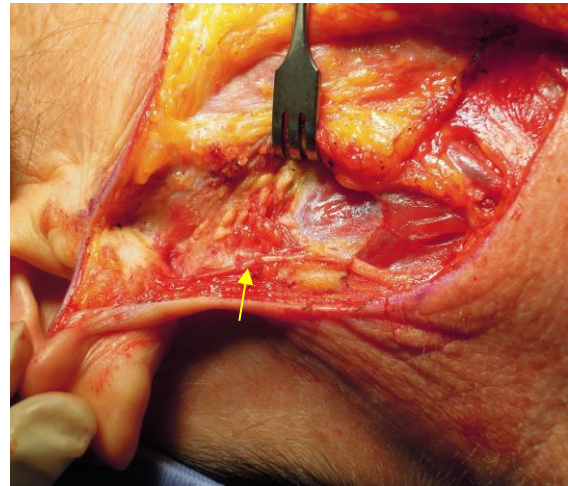


Figure 17: Posterior branch of greater auricular nerve (arrow)

- Identify and skeletonise the posterior belly of the digastric muscle. Do not dissect cephalad of the muscle as one may injure the facial nerve (Figure 16)
- Skeletonise the cartilage of the external auditory canal up to the tragal pointer. This can be done quite quickly with electrocautery dissection as the facial nerve exits the stylomastoid foramen 1cm deep to the tragal pointer
- Skeletonise the mastoid tip to the depth of the tragal pointer
- Identify all the following landmarks for the facial nerve (Figures 12, 13 & 18)
  - Tragal pointer (nerve 1 cm deep and inferior)
  - Tympanic ring
  - Anterior aspect of mastoid bone
  - Tympanomastoid suture line (leads directly to stylomastoid foramen)
  - Posterior belly of digastric muscle (Facial nerve at same depth, just above muscle)
  - Palpate the styloid process (facial nerve in angle between styloid and digastric, and crosses styloid more anteriorly)
- Locate the facial nerve trunk by blunt dissection with a fine haemostat (Figures 18, 19)



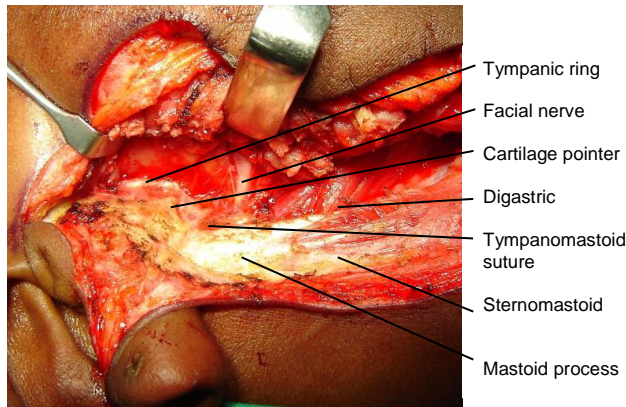


Figure 18: Identify facial nerve landmarks

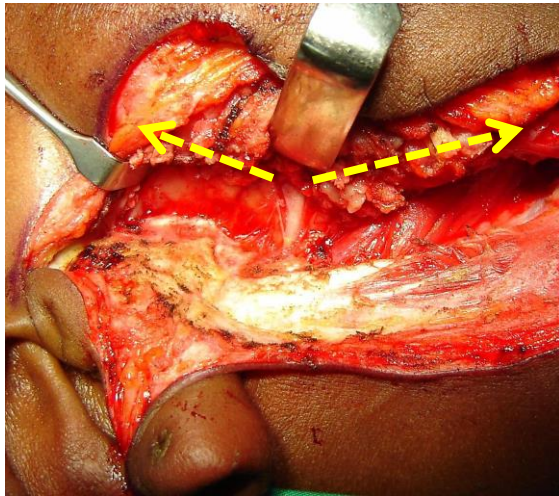


Figure 19: Location of facial nerve trunk, and superior and inferior release of capsule and parotid tissues (yellow arrows)

- Use fine curved blunt tipped scissors for the remainder of the nerve dissection. Tunnel and spread the tissues overlying the facial nerve and its branches, and divide the parotid tissue overlying the nerve. It is important to dissect directly on the nerve so as not to lose sight of it. **Never** divide parotid tissue beyond exposed facial nerve. Wearing loupes e.g. with 2.5x magnification assists with the dissection, and enables one to better distinguish between blood vessels and nerves. Employ bipolar diathermy and fine silk ties for haemostasis.
- Dissect along the trunk to the *pes anserinus*

- Dissect back towards the stylomastoid foramen to exclude early branching from the trunk
- Divide the parotid fascia and parotid tissue superiorly and inferiorly to release the parotid posteriorly and to permit anterior mobilisation of the gland/tumour (Figure 19)
- Dissect along, and strip the superficial lobe off the branches of facial nerve. Unless a complete superficial parotidectomy is done, only the branches close to the mass are dissected and exposed (Figure 20)

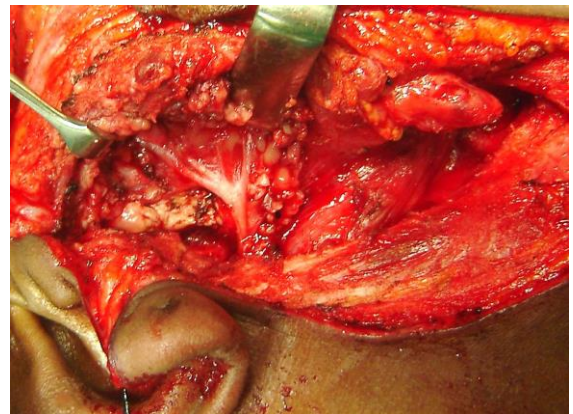

Figure 20: Strip the superficial lobe off the branches of facial nerve

- Identify the retromandibular vein as it crosses the medial to the facial nerve (Figure 21)

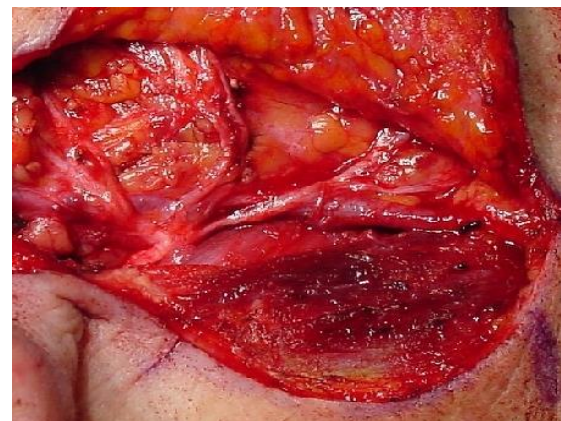


Figure 21: Completed superficial parotidectomy; note nerve crossing retromandibular vein

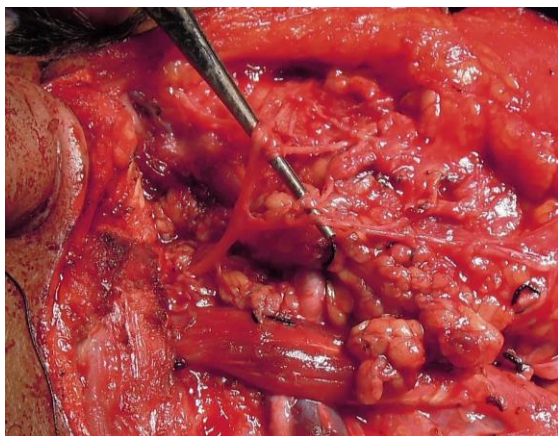

- If removing the superior part of the gland, identify/ligate the superficial temporal artery superiorly, just anterior to auricle
- If dissecting to the anterior border of the gland, identify and transect the parotid duct
- Remove the tumour with a cuff of the superficial parotid lobe

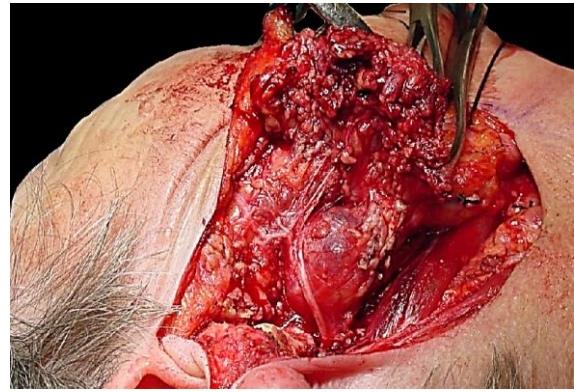
### Parotid dissection for deep lobe tumours

The principles of resecting deep lobe tumours are to:

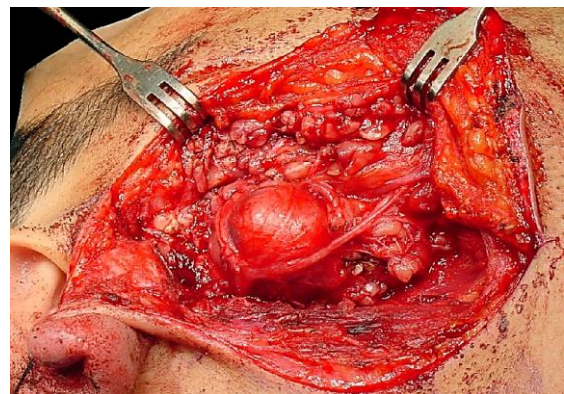
- Identify, dissect and free up the facial nerve from the underlying deep lobe or tumour, to provide access to the deep lobe. This may involve either a superficial parotidectomy (*Figure 22*), or simply reflecting the superficial lobe anteriorly, keeping the parotid duct intact, and replacing it at the conclusion of surgery (*Figure 23*)
- Deliver the tumour either between, or inferior to the facial nerve or its branches, identifying the branches of the facial nerve around the tumour, and removing tumour between the splayed facial nerve branches (*Figure 24*)



*Figure 22: Facial nerve has been freed from deep lobe*



*Figure 23: Reflecting superficial lobe for access to facial nerve and to deep lobe tumour*



*Figure 24: Tumour resected by removing tumour between splayed facial nerve branches*

- The deep lobe of the parotid/tumour is bordered medially by the fat of the parapharyngeal space, and can be delivered from the parapharyngeal space by blunt dissection
- Be prepared to divide the external carotid, deep transverse facial and superficial temporal arteries and the retro-mandibular and superficial temporal veins if and when they are encountered during dissection
- Additional access may be provided to the deep aspect of a tumour by dividing the styloid process and/or via a trans-cervical approach (*Figure 25*)

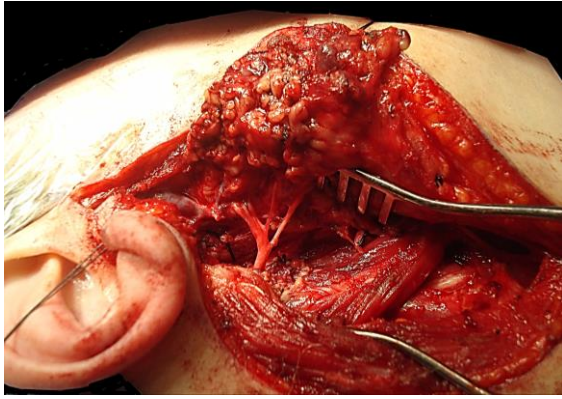


Figure 25: Access to parapharyngeal space tumour extension by reflecting the superficial lobe and division of styloid process

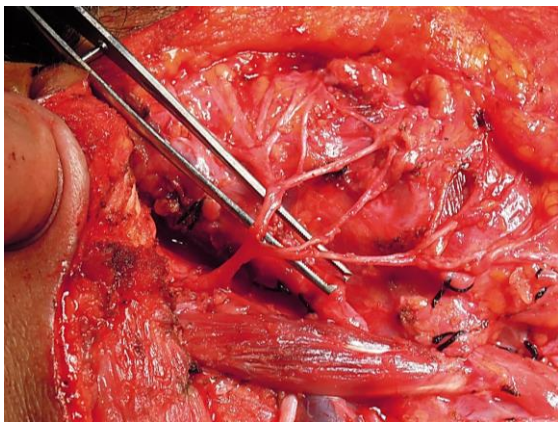


Figure 26: Completed total parotidectomy in patient shown in Figure 22; silk ties are on branches of the external carotid artery

### Tumour spillage

Great care should be taken to avoid rupture and spillage of pleomorphic adenoma tissue into the operative site as it may lead to multifocal tumour recurrence, often more than 20yrs following surgery (Figure 27). A minor controlled capsular rupture may be simply managed by copiously irrigating the wound. With more extensive ruptures, especially of a pleomorphic adenoma in the parapharyngeal space, some would advocate postoperative radiation therapy. Due to the multifocal nature of the recurrence, MRI is an important preoperative investigation for recurrence. Having to operate in a previously dissected field, the facial nerve is

at greater risk of injury, and should be monitored during surgery.

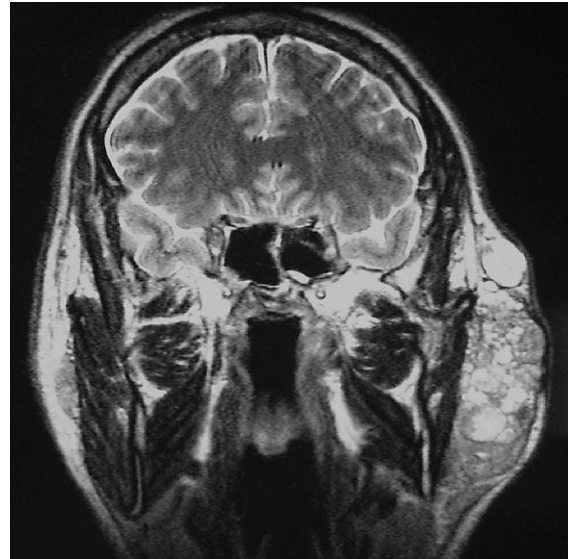


Figure 27: Multifocal recurrence of pleomorphic adenoma

### Wound closure

- **Confirm nerve continuity:** Carefully inspect the nerve. One may stimulate the nerve with a nerve stimulator. Neuropraxia due to mechanical trauma may however cause failure of muscle contraction
- **Obtain meticulous haemostasis:** Use ties and bipolar diathermy. Employ a Valsalva manoeuvre to identify venous bleeding
- **Sealed suction drain:** Until drainage <50ml/24 hrs
- **Skin closure:** Subcutaneous and subcuticular absorbable sutures

### Facial nerve repair

Unlike with malignant tumours, the facial nerve and its branches can virtually always be dissected free from benign neoplasms. Isolated midfacial branches may be sacrificed without causing visible facial dysfunction. Transection of the temporal (frontal)



and marginal mandibular nerves however results in disfiguring facial asymmetry; these nerves should be repaired with 8/0 nylon/prolene epineural sutures. When primary nerve repair is not possible due to undue tension or nerve resection, then the nerve can be grafted with greater auricular nerve, or sural nerve.

The **greater auricular nerve** is approximately the same diameter as the facial nerve trunk, and has a few branches that can be used to graft more than one facial nerve branch (Figure 28).

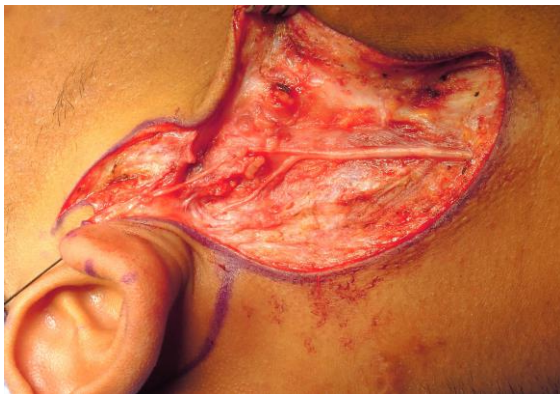

Figure 28: Greater auricular nerve

The **sural nerve** provides greater length and more branches and is better suited to bridging longer defects and for grafting to more peripheral branches (Figures 29, 30).

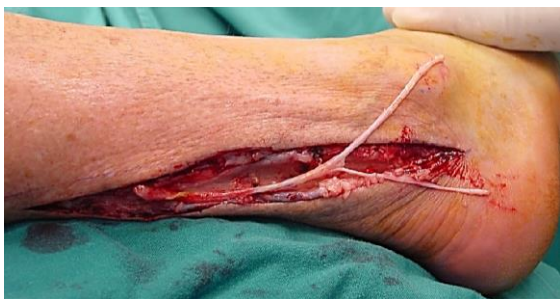

Figure 29: Sural nerve

When the proximal end of the facial nerve is not available, e.g. with extensive proximal perineural tumour extension, then a **hypoglossal-facial nerve interposition graft** can

be used to restore facial tone and movement. The nerve graft is sutured end-to-end to the distal facial nerve(s), and end-to-side to the hypoglossal nerve after cutting about 25% into the side of the hypoglossal nerve to expose the nerve axons (Figure 31).

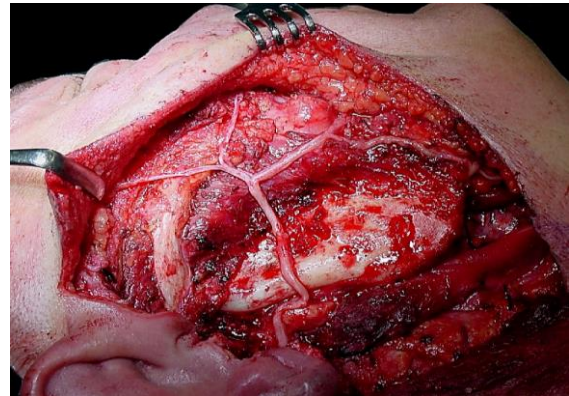

Figure 30: Sural nerve graft

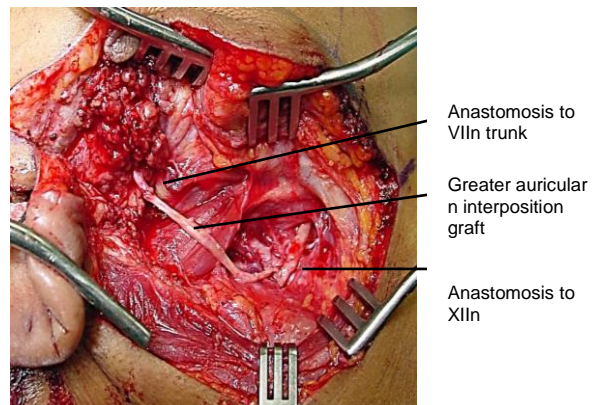


Figure 31: Hypoglossal/facial nerve graft

## Author & Editor

Johan Fagan MBChB, FCORL, MMed  
Professor and Chairman  
Division of Otolaryngology  
University of Cape Town  
Cape Town, South Africa  
[johannes.fagan@uct.ac.za](mailto:johannes.fagan@uct.ac.za)