

ORTHOPAEDICS



FOR PRIMARY
HEALTH CARE



LION

LEARNING INNOVATION VIA
ORTHOPAEDIC NETWORKS

EDITOR: **MICHAEL HELD**

UNIVERSITY OF CAPE TOWN'S **ORTHOPAEDIC DEPARTMENT**

Upper limb soft tissue injuries

by Kirsty Berry, Shaun De Villiers & Marc Nortje

Learning objectives

1. Have an approach to upper limb soft tissue injuries.
2. Diagnose common soft tissue injuries of the upper limb.
3. Understand basic management principles of these injuries.

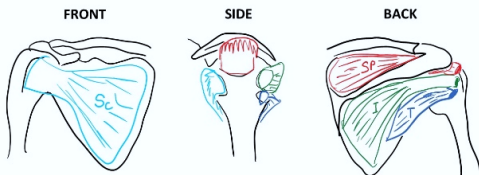
Introduction

Most of the ligament, tendon and muscle injuries of the upper limb can be treated by trying conservative management. The majority of these injuries present to the general practitioner and emergency units and not the specialist orthopaedic surgeon.

Rotator cuff injuries

Tears of the rotator cuff tendons tend to occur in people over the age of 50 years and may be due to general attrition of the tendon with age. There may or may not be an associated injury.

Applied anatomy



Rotator cuff muscles around the shoulder

The rotator cuff consists of four muscles, the subscapularis (Sc), supraspinatus (Sp), infraspinatus (I) and teres minor (T). These muscles are responsible for the movements of the glenohumeral joint.

Muscle	Action	Strength testing
Supraspinatus	Initiates abduction	Weakness to resisted elevation in Jobe position
Infraspinatus	External rotation	External rotation in 0° abduction External rotation in 90°
Teres minor	External rotation	abduction and 90° external rotation
Subscapularis	Internal rotation	Internal rotation in 0° abduction

Actions of the rotator cuff muscles

Clinical findings

History

Pain

- Insidious onset.
- Often night pain.
- It is exacerbated by overhead activities.

- In the event of a traumatic tear, the pain and weakness are acute.

Weakness

- Loss of active range of motion with greater passive range of motion.

Examination

The same as for impingement syndrome, but there is additional weakness on the resisted movement of the rotator cuff muscles.

Additional injuries to note

The bruised shoulder with normal X-rays following trauma:

- The patient has an occult fracture or a torn rotator cuff. Subscapularis tears are most commonly missed and are tested with the Belly Press and Gerber's lift-off test.
- If the patient is no better after ten days, another careful examination and further imaging such as an ultrasound or MRI are necessary.

Imaging

X-rays

Shoulder – look for:

- Calcific tendonitis of the supraspinatus tendon insertion.
- Cystic changes in greater tuberosity are a sign of a chronic tear.
- Proximal migration of the humerus can be seen with chronic RCT (acromiohumeral interval <7 mm).
- Type III (hooked) acromion

Ultrasound

- Suspicion of rotator cuff pathology.

- Able to perform dynamic examination.
- Relatively low cost, if available.

MRI

Expensive, so only use in a young patient with traumatic tears or pain or weakness attributable to a rotator cuff tear that does not improve with conservative management.

Management

Non-surgical

- Physiotherapy, activity modification, NSAIDs, subacromial corticosteroid injections.
 - The first line of treatment for most tears.

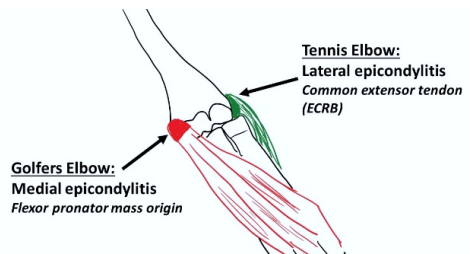
Surgical

- Failure of conservative treatment.
- Repair of rotator cuff +/- subacromial decompression (open or arthroscopic).

Tennis and golfer's elbow

This is an overuse syndrome of the lateral epicondyle (tennis elbow) and medial epicondyle (golfer's elbow).

Applied anatomy



The flexor-pronator mass origin is affected in golfer's elbow, and the common extensor tendon is affected in tennis elbow

Overuse injuries due to eccentric overload at the common extensor tendon lead to tendinosis and inflammation at the origin of ECRB, commonly known as tennis elbow. The same pathology exists for the medial epicondyle where the flexor-pronator mass origin is involved and is known as golfer's elbow.

Clinical findings

History

Pain

- Insidious onset.
- It is localised over medial or lateral epicondyles.
- Worse with wrist and forearm motion and gripping.

Examination

- Point tenderness 5-10mm distal and anterior to the medial epicondyle (golfer's) and tenderness at ECRB insertion into lateral epicondyle (tennis).
- Provocative tests:
 - Lateral epicondyle: resisted wrist extension with the elbow fully extended.
 - Medial epicondyle: pain with resisted forearm pronation and wrist flexion.

Imaging

X-rays

- Usually normal.
- May show calcification in the tendons.

Ultrasound

- Not necessary for diagnosis.

- Allow dynamic examination.
- Operator-dependant.
- Shows areas of focal degeneration, but mostly normal.

MRI

- Not necessary for diagnosis.
- Standard of care for medial epicondylitis.

Management

Non-surgical

- Rest, ice, physiotherapy, activity modification, bracing and NSAIDs.
 - The first line of treatment for most.

Surgical

- Open debridement of origin.

Essential takeaways

- Tears of the rotator cuff tendons tend to occur in people over the age of 50 years.
- The bruised shoulder, with a normal X-ray after trauma, should be investigated.
- Tennis elbow and golfer's elbow are primarily diagnosed with clinical examination and history.
- Non-surgical management is the first line of treatment with most.

References

Amin NH, Kumar NS, Schickendantz MS. Medial epicondylitis: evaluation and management. JAAOS. 2015; 3(6):348–55

Dines JS, Bedi A, Williams PN, et al. Tennis injuries: epidemiology, pathophysiology, and treatment. JAAOS. 2001; 23(3): 181–9

Millett PJ, Warth RJ. Posterolateral rotator cuff tears: classification, pattern recognition, and treatment. JAAOS. 2014 Aug; 22(8):521–34.

Assessment

A 40-year-old man presents to the clinic with three months of right elbow pain. He started playing squash four months previously. On examination, he is tender over the lateral aspect of the elbow and pain increases with resisted wrist extension. Which of the following muscles is involved in the pathophysiology of this disease?

- A. FCU – Flexor carpi ulnaris.
- B. FCR – Flexor carpi radialis.
- C. FDS – Flexor digitorum communis.
- D. ECRB – Extensor carpi radialis brevis.

(D) is correct, as the patient presents with lateral epicondylitis which involves the origin of the ECRB. The other muscles are all flexor muscles and are involved in medial epicondylitis.

Editor: Michael Held

Conceptualisation: Maritz Laubscher & Robert Dunn

Cover design: Carlene Venter
(Creative Waves Brand Design)

Developmental editing and design:
Vela Njisanane and Phinda Njisanane

ABOUT THE BOOK

Informed by experts: Most patients with orthopaedic pathology in low to middle-income countries are treated by non-specialists. This book was based on a modified Delphi consensus study* with experts from Africa, Europe, and North America to provide guidance to these health care workers. Knowledge topics, skills, and cases concerning orthopaedic trauma and infection were prioritised. Acute primary care for fractures and dislocations ranked high.

Furthermore, the diagnosis and the treatment of conditions not requiring specialist referral were prioritised.

* Held et al. Topics, Skills, and Cases for an Undergraduate Musculoskeletal Curriculum in Southern Africa: A Consensus from Local and International Experts. JBJS. 2020 Feb 5;102(3):e10.

THE LION

The Learning Innovation via Orthopaedic Network (LION) aims to improve learning and teaching in orthopaedics in Southern Africa and around the world. These authors have contributed the individual chapters and are mostly orthopaedic surgeons and trainees in Southern Africa who have experience with local orthopaedic pathology and treatment modalities but also in medical education of undergraduate students and primary care physicians. To centre this book around our students, iterative rounds of revising and updating the individual chapters are ongoing, to eliminate expert blind spots and create transformation of knowledge.

DISCLAIMERS

Although the authors, editor and publisher of this book have made every effort to ensure that the information provided was correct at press time, they do not assume and hereby disclaim any liability to any party for any loss, damage, or disruption caused by errors or omissions, whether such errors or omissions result from negligence, accident, or any other cause.

This textbook is not intended as a substitute for the medical advice of physicians. The reader should regularly consult a physician in matters relating to his/her health and particularly with respect to any symptoms that may require diagnosis or medical attention.

The information in this book is meant to supplement, not replace, Orthopaedic primary care training. The authors, editor and publisher advise readers to take full responsibility for their safety and know their limits. Before practicing the skills described in this book, be sure that your equipment is well maintained, and do not take risks beyond your level of experience, aptitude, training, and comfort level.

The individual authors of each chapter are responsible for consent and rights to use and publish images in this book.

© The Authors 2021



Licensed under a Creative Commons Attribution (CC BY) 4.0 International Licence.

ACKNOWLEDGEMENTS

This work was carried out with the aid of a grant from the International Development Research Centre, Ottawa, Canada. Thanks to Johan Fagan, Michelle Willmers and Glenda Cox for their mentorship and support.