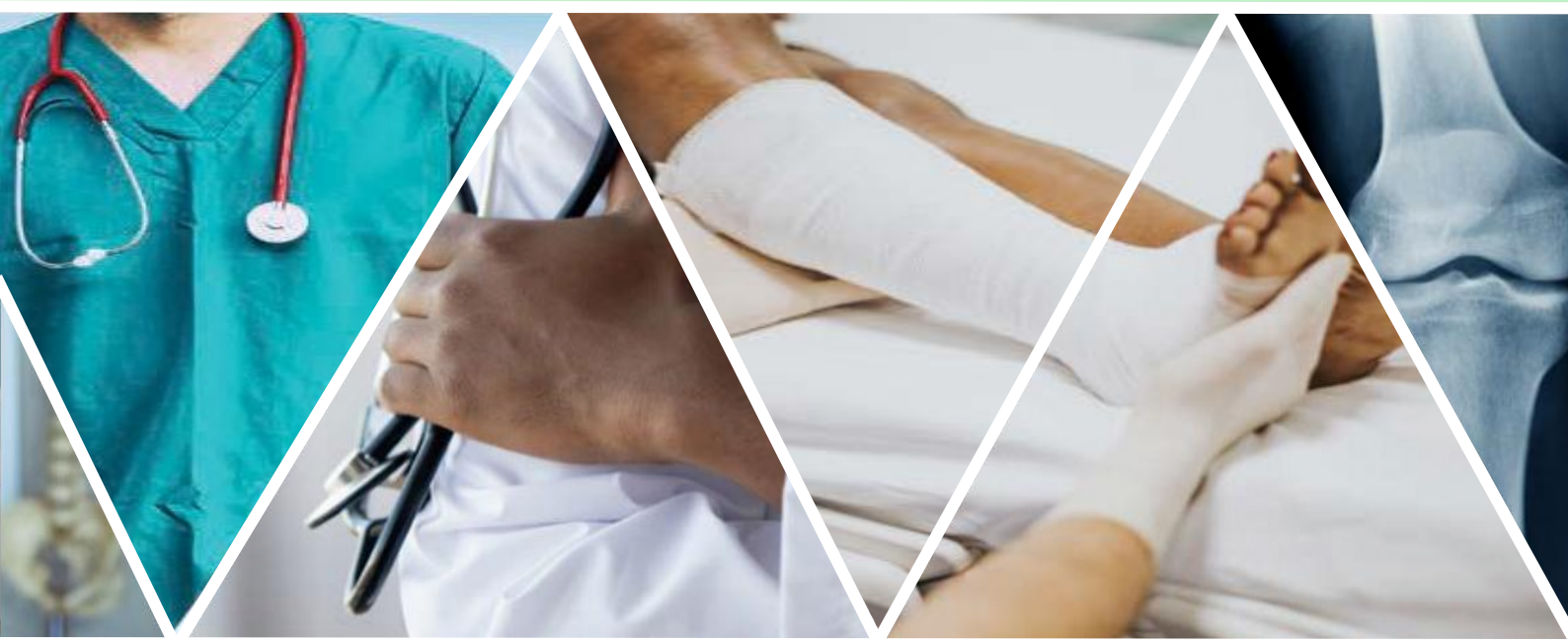

ORTHOPAEDICS

FOR PRIMARY HEALTH CARE



Volume 2

Non-Emergency and Non-Trauma Pathology

Edited by Michael Held

ORTHOPAEDIC DEPARTMENT
UNIVERSITY OF CAPE TOWN

Approach to a swollen, painful limb in a child

By Anria Horn

Learning objectives

- Know the differential diagnosis for a swollen, painful limb in a child.
- Know which pertinent questions to ask during the history taking.
- Know the key clinical features to aid diagnosis.
- Know which special investigations to perform.
- Know the indications for urgent referral.

Case presentation

A 2-year-old male presents with a history of limping and progressive swelling over the left lower leg and ankle.

The caregiver is uncertain of when exactly it started, but the swelling has been getting worse over the last 2 weeks.

There is no history of trauma or prior illness. The child is developmentally normal.

Examination reveals a large mass on the medial aspect of the lower leg. There are no skin changes noted over the mass, nor are there any scars.

The mass is soft. It is tender to palpation. It appears to be adherent to the underlying bone. It is not warm compared to the other leg.

The ankle can be moved passively, although the child does not move it actively. Distal pulses and movement are intact.

Vital signs are within normal limits.

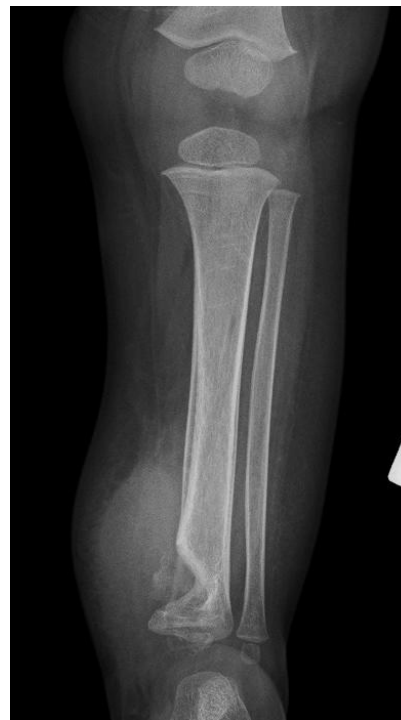

Figure 1: A lesion in the metaphysis of the distal tibia

There is a lesion affecting the medial distal metaphysis of the tibia. The lesion has sclerotic margins and is well demarcated. There is a significant soft tissue component as is evidenced by a soft tissue mass medially. There is some calcification in the lesion. There is a periosteal reaction on the medial diaphysis. These x-ray features are

suggestive of a slow-growing or chronic lesion. The differential diagnosis includes infection or a low-grade tumour.

Blood investigations reveal a raised C-reactive protein (CRP) and erythrocyte sedimentation rate (ESR), a mild anaemia and a raised platelet count.

Magnetic resonance imaging (MRI) was performed.

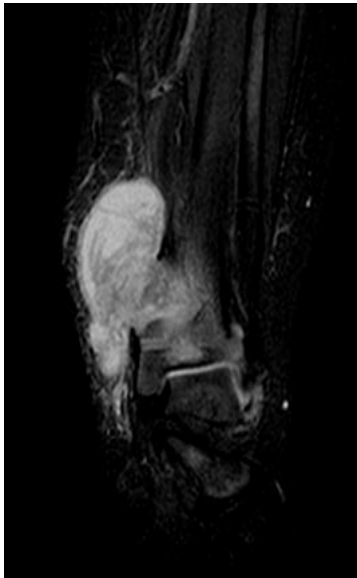


Figure 2: Coronal MRI scan showing a large bone abscess involving the metaphysis and epiphysis of the distal tibia, extending outside the cortex

Radiologically and clinically, tuberculosis (TB) was diagnosed and this was confirmed on biopsy. The patient was treated medically and the lesion healed.

Introduction

When assessing a child with a painful, swollen limb, the diagnosis will typically fall into 1 of 4 categories: trauma, infection (acute or chronic), tumour (benign or malignant) and inflammatory.

The differential diagnosis can be narrowed down by a thorough history and clinical examination.

Once the differential diagnosis has been narrowed down, appropriate special investigations are performed and treatment instituted.

History

Duration: A condition that has been present for months and progressing slowly is less likely to require emergency treatment than a recent-onset, painful and swollen limb (for example, TB vs acute haematogenous osteitis).

Precipitating events: Was there a traumatic event preceding the swelling of the limb? If so, how soon after the injury did it start? Was there a preceding infection such as tonsillitis or otitis media? If the pain and swelling occurred immediately after a traumatic event, a fracture or other injury is most likely. If, however, there was a delay in onset of symptoms, bone or joint infection is highly likely.

Progression: Is the pain and swelling getting worse or better? Traumatic conditions tend to improve over time, unlike infectious or malignant conditions.

Associations: Constitutional symptoms such as malaise and weight loss are suggestive of chronic infections or malignancy. Other joint involvement is suggestive of an inflammatory condition. Fever is fairly non-specific, but typically absent in the traumatic setting.

Past medical and surgical history:

This may give a clue to the underlying condition. Also ask if any treatment has been sought before and what this was.

Examination

Look

- Which part of the limb is involved? Is the swelling localised or diffuse?

- Is the skin inflamed (red)? If so, a superficial infection may be the cause.
- Is there induration or blistering? Suggestive of cellulitis or necrotising fasciitis.
- Is there a skin lesion or sinus? Chronic infection likely.
- Scarification? This would suggest a chronic or long-standing condition.
- Previous surgical scars?

Feel

- Warmth is indicative of inflammation or infection.
- Consistency: Tensely swollen limbs typically indicate trauma or a generalised infection. Fluctuant swelling indicates an abscess or haematoma. Soft, spongy swellings are unusual and may indicate a soft tissue mass or vascular malformation.
- Is there an associated joint effusion?
- Distal neurovascular status?

Move

Are you able to move the adjacent joints? Frozen joints are very typical of infections, but patients with fractured limbs are also reluctant to move the adjacent joints.

Special investigations

Plain film x-rays

X-rays will always be the first investigation you request. If there is a fracture, you will have your diagnosis and no further investigations will be required.

Do not routinely request contralateral limb x-rays, as they add additional cost and radiation and are not always necessary. Reserve those for cases of uncertainty.

In acute infections and inflammatory

conditions, x-rays are typically normal, although you may be able to appreciate the soft tissue swelling.

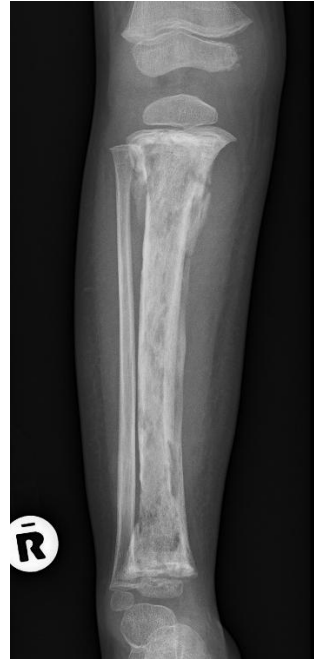

Figure 3: An x-ray of a young child with chronic osteomyelitis of the tibia. Note the irregular cortices, areas of lysis and sclerosis, as well as the developing sequestrum and involucrum. There is a pathological fracture in the proximal metaphyses. The epiphyses are spared and the fibula appears normal.

Blood investigations

Baseline tests to request are a FBC (full blood count), CRP and ESR. If you suspect an infection, take a blood culture at the same time. It is usually not necessary to test renal and liver function.

Normal baseline bloods exclude infection, malignancy and inflammation. Abnormal baseline bloods are non-specific, but there are certain trends to look out for:

- Acute infections usually have a very high CRP and a raised white cell count.
- TB typically has a raised ESR, normal white cell count, mild anaemia and high platelets.

- Malignant conditions often present with severe anaemia, very high ESR but modestly raised CRP.

Other investigations

MRI is the most specific investigation available. It can detect very early changes in cases of infection, and it can differentiate accurately between different pathologies that may cause a painful, swollen limb. Figure 4a shows a 12-year-old boy who presented with thigh swelling and pain. X-rays and blood investigations were normal. MRI demonstrated a large vascular malformation in the thigh.

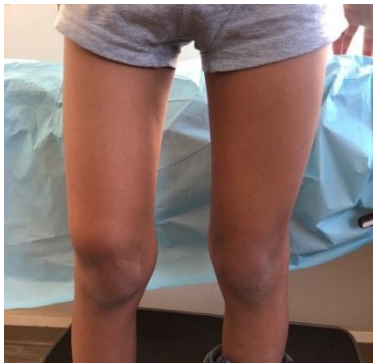

Figure 4a: 12-year-old boy presenting with thigh swelling and pain

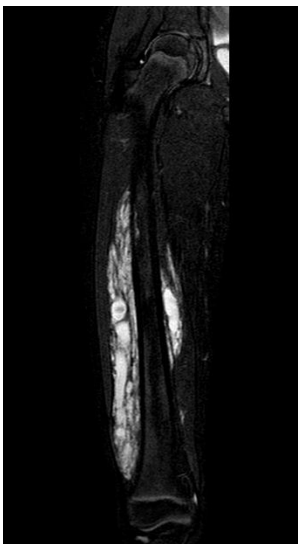


Figure 4b: MRI demonstrating large vascular malformation in the thigh

Bone scans are very useful investigations if the exact location of the pathology is unclear. This is typically the

case in young, limping children with swollen, painful limbs where examination is difficult and often inconclusive. Bone scans are very sensitive, but not very specific and are not widely available.

Ultrasound is widely available and inexpensive. It can distinguish between solid masses and collections and can diagnose the rare case of deep vein thrombosis in children. Ultrasound is quite user-dependent and not very accurate in detecting small sub-periosteal collections.

Biopsy

Patients presenting with a painful, swollen limb in the absence of acute trauma will most likely require a biopsy of some sort. In cases of clear infection, this will form part of the incision and drainage (I&D) of the abscess and lead to pathogen identification and antimicrobial sensitivity. In tumours, a biopsy is always required prior to the initiation of treatment.

Once you suspect a bone or joint infection or a tumour, the patient should be referred to a centre with the required expertise immediately.

Red flags

Features suggestive of sepsis:

- Fever.
- Tachycardia.
- Inability to weight-bear or actively move the joint.
- Rapidly progressive pain.
- Features suggestive of malignancy:
- Progressive pain and swelling in the absence of features of sepsis.
- Anaemia.
- Weight loss and malaise.

Key takeaways

- Second to trauma, infection is the most common cause of a painful, swollen limb in a child and should always be actively excluded.
- Although the differential diagnosis is broad, a targeted history and examination will aid in the diagnosis.
- Once infection or malignancy is confirmed or suspected, urgent referral is required.

References and further reading

Weinstein, S., & Flynn, J. M. (2014). Lovell and Winter's paediatric orthopaedics. 7th Edition. Wolters Kluwer, Philadelphia, USA.

Vajapey, S., & Horn, A. (2021) Tuberculosis of the extra-axial skeleton in children. South African Orthopaedic Journal, 20(1).

Editor: Michael Held

Conceptualisation: Maritz Laubscher & Robert Dunn

Publishing Manager: Michelle Willmers

Cover design: Adapted from first edition cover design by Carlene Venter

Proofreading and page layout: Robyn Brown

ABOUT THE BOOK

This is the second volume of the *Orthopaedics for Primary Health Care* textbook edited by Michael Held, first published in 2021.

Most patients with orthopaedic pathology in low- and middle-income countries are tested by non-specialists. This book was based on a Delphi consensus study* with experts from Africa, Europe and North America to identify topics, skills and cases concerning orthopaedic trauma and infection that need to be prioritised in order to provide guidance to these health care workers.

The aim of this book is to be student-centred.

*Held et al. Topics, Skills, and Cases for an Undergraduate Musculoskeletal Curriculum in Southern Africa: A Consensus from Local and International Experts. JBJS. 2020 Feb 5;102(3):e10.



© The Authors 2025. Licensed under a Creative Commons Attribution (CC BY) 4.0 International Licence.

DISCLAIMER

Although the authors, editor and publisher of this book have made every effort to ensure that the information provided was correct at press time, they do not assume and hereby disclaim any liability to any party for any loss, damage, or disruption caused by errors or omissions, whether such errors or omissions result from negligence, accident, or any other cause.

This textbook is not intended as a substitute for the medical advice of physicians.

The information in this book is meant to supplement, not replace, orthopaedic primary care training.

The authors, editor and publisher advise readers to take full responsibility for their safety and know their limits. Before practicing the skills described in this book, be sure that your equipment is well maintained, and do not take risks beyond your experience, aptitude, training or comfort level.

The individual authors of each chapter are responsible for consent and rights to use and publish images in this book.

ACKNOWLEDGEMENTS

Thanks to the Orthopaedic Department in the Faculty of Health Sciences and the Centre for Innovation in Learning and Teaching in the Centre for Higher Education Development at the University of Cape Town for the support received in the development of this publication.